TRAITÉ
D'ANATOMIE
DESCRIPTIVE,

RÉDIGÉ

D'APRÈS L'ORDRE ADOPTÉ A LA FACULTÉ DE MÉDECINE DE PARIS.

PAR M. H. CLOQUET.

PLANCHES.

ANGÉIOLOGIE.

CET ATLAS SE DIVISE EN CINQ PARTIES QUI SE VENDENT SÉPARÉMENT.

OSTÉOLOGIE. . . 39 Pl. fig. n. : 15 fr.; fig. col. : 22 fr. | NÉVROLOGIE . . 36 Pl. fig. n. : 10 fr.; fig. col. : 25 fr.
MYOLOGIE. . . . 36 Pl. fig. n. : 10 fr.; fig. col. : 25 fr. | ANGÉIOLOGIE. . 60 Pl. fig. n. : 18 fr.; fig. col. : 38 fr.
SPLANCHNOLOGIE et EMBRYOLOGIE. . . . 43 Pl. fig. n. : 12 fr.; fig. col. : 27 fr.

PARIS.
LIBRAIRIE MÉDICALE ET SCIENTIFIQUE DE CROCHARD,
PLACE DE L'ÉCOLE DE MÉDECINE, N. 13.

1835.

18102/C
.18102/C
Atlas pt iv. Plates

4247
57650

WELLCOME
HISTORICAL
MEDICAL
LIBRARY

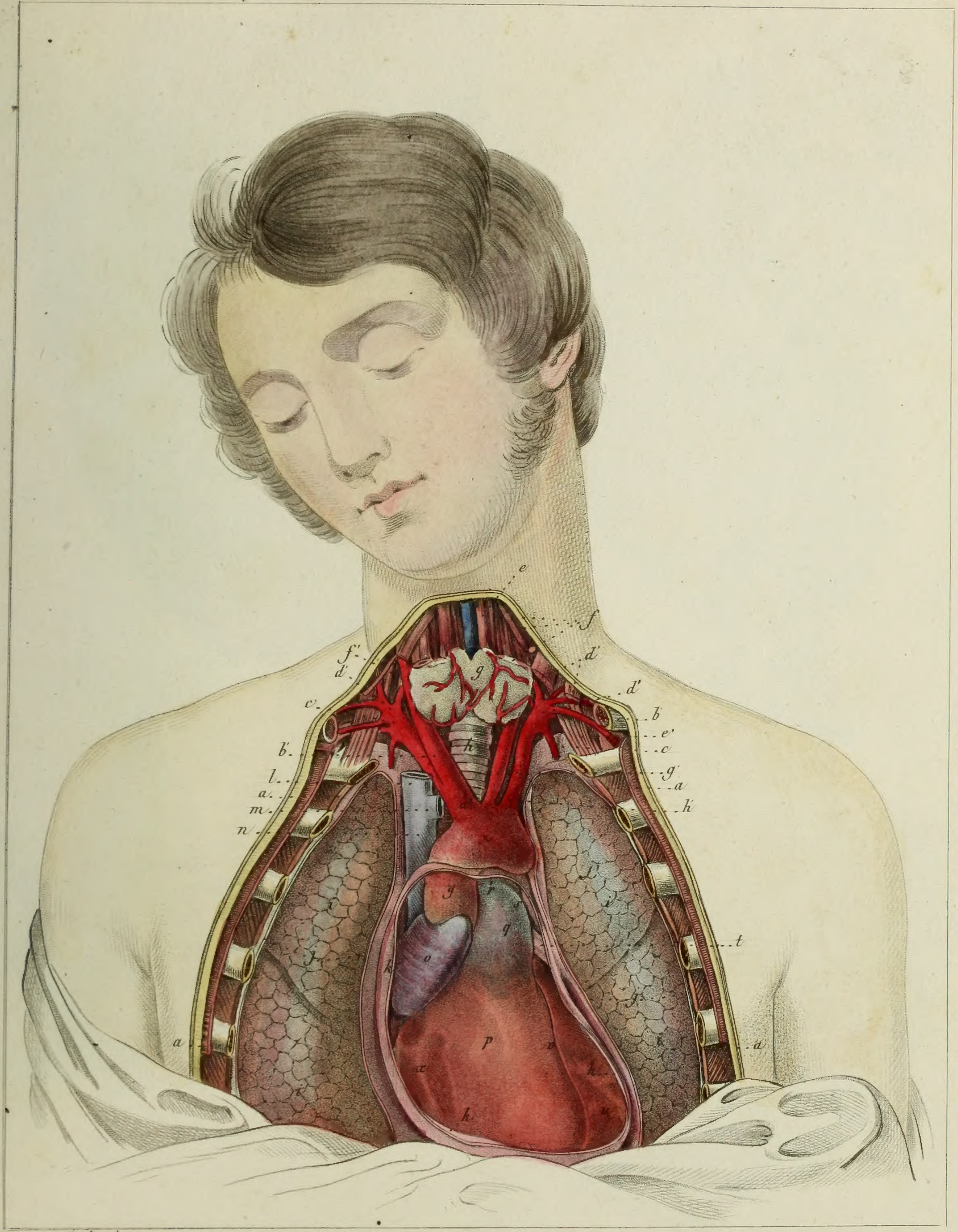

P. Duménil Dir.t

CROSSE DE L'AORTE

Digitized by the Internet Archive
in 2016

https://archive.org/details/b22014688_0004

Fig. 4.

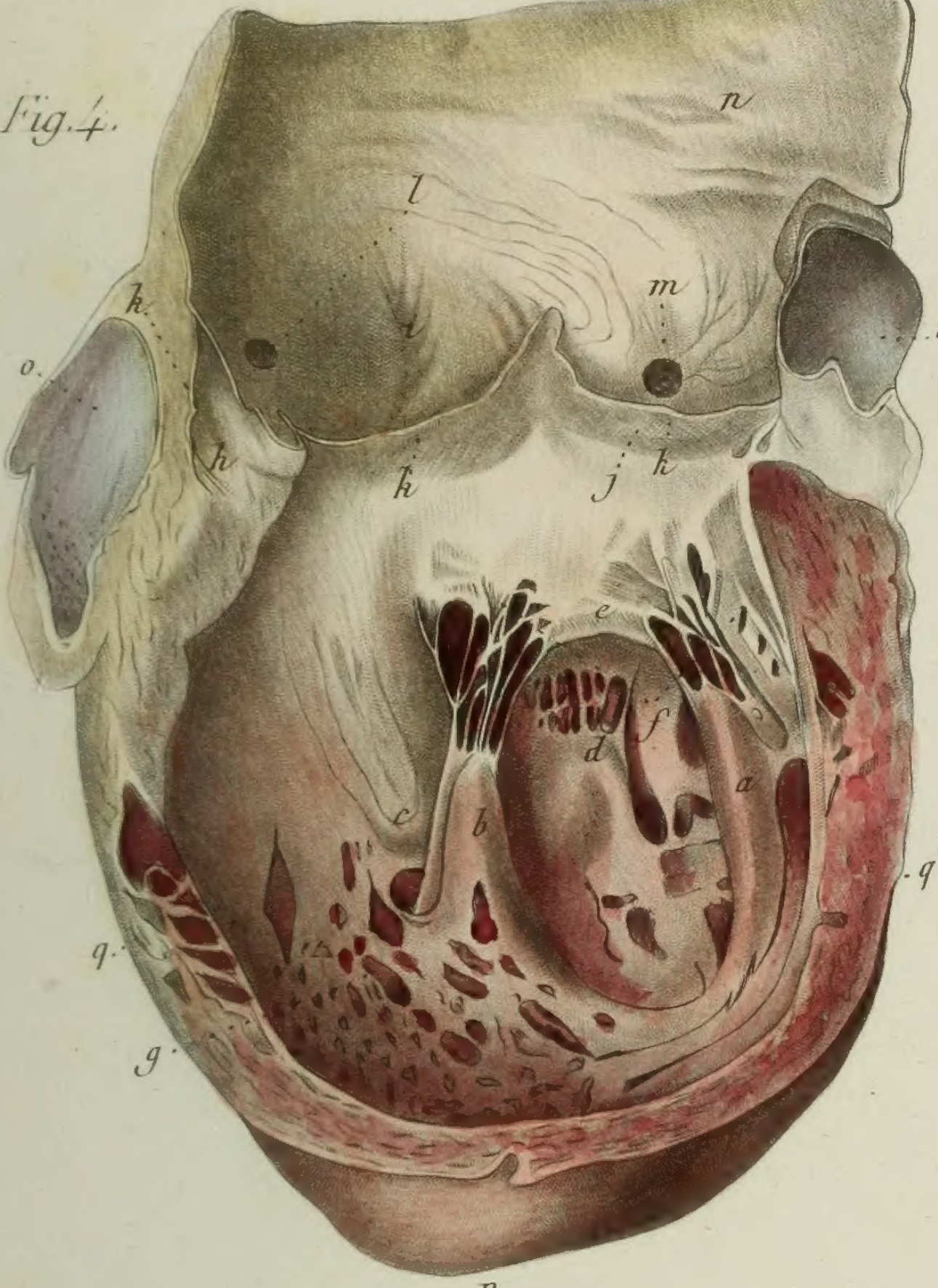

Fig. 2

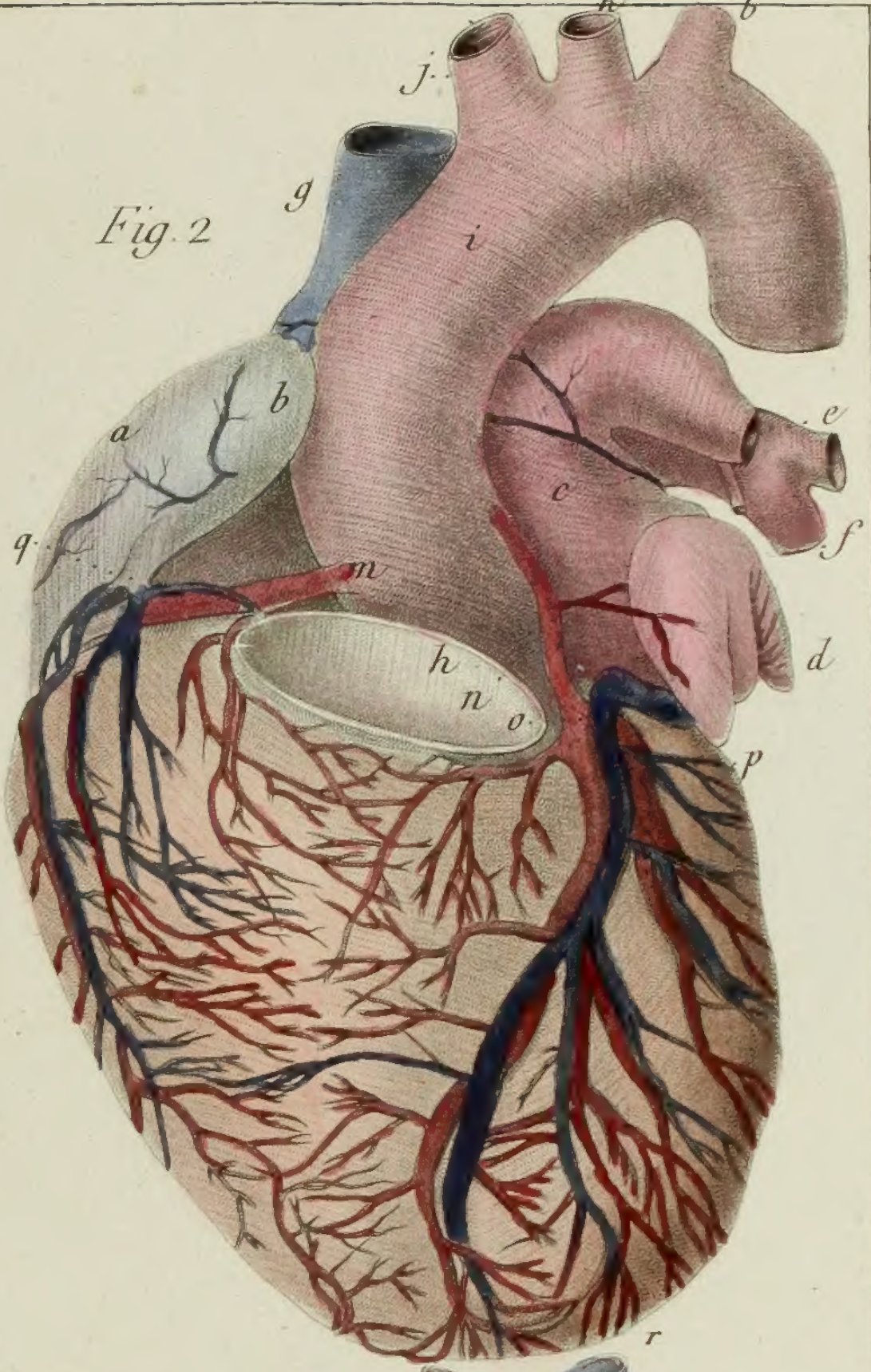

Fig. 3.

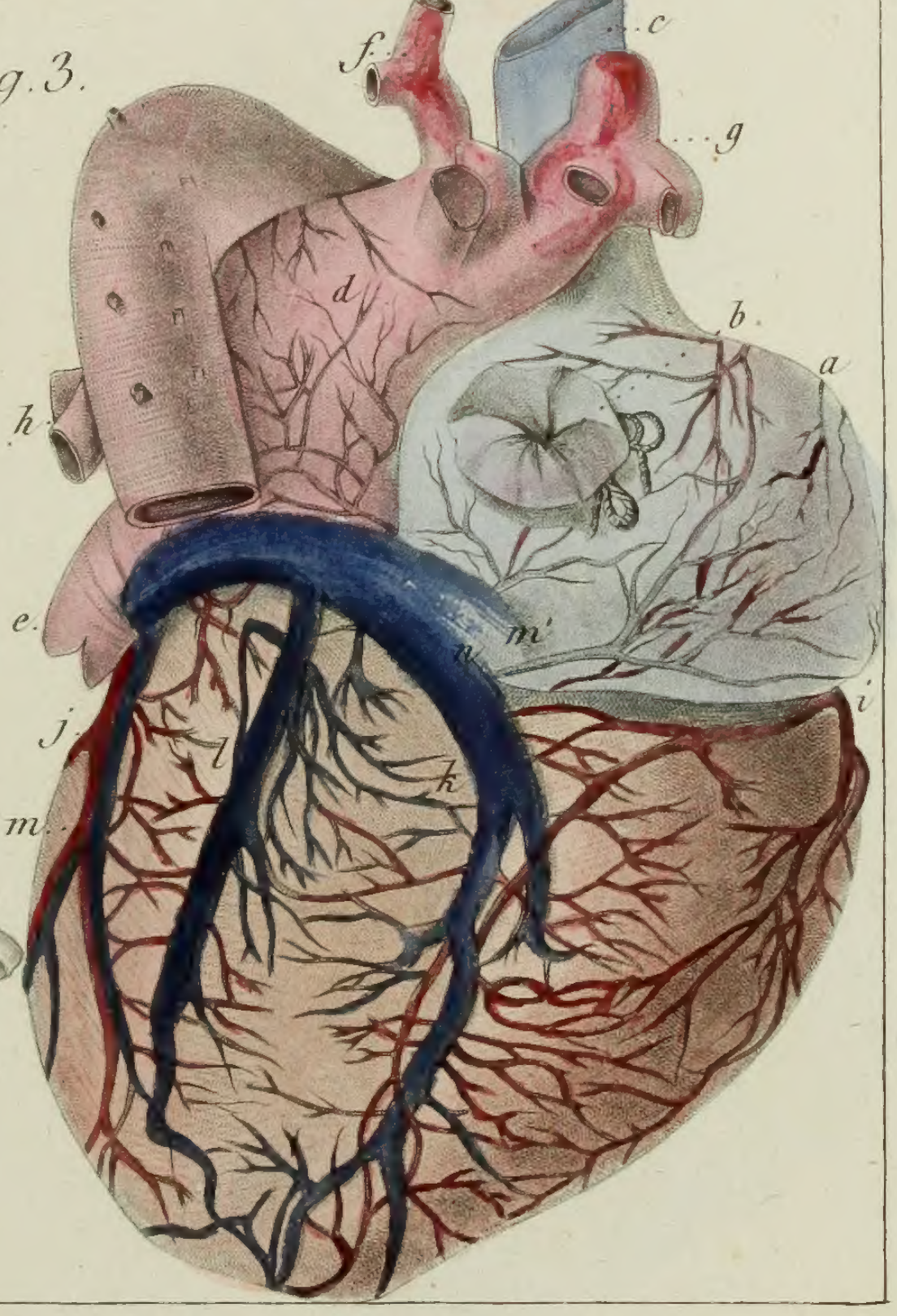

Fig. 1.

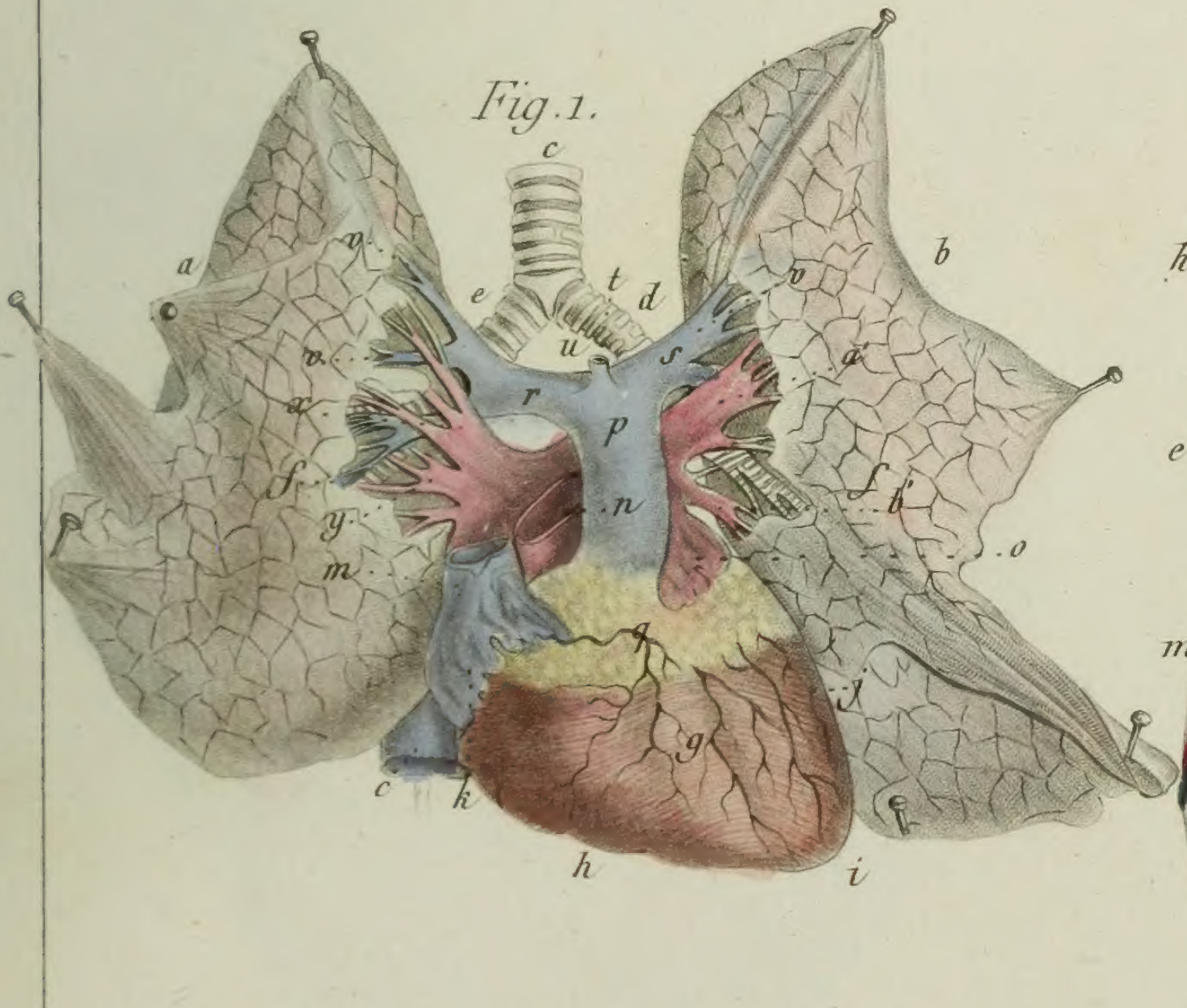

CŒUR; ARTÈRES CORONAIRES.

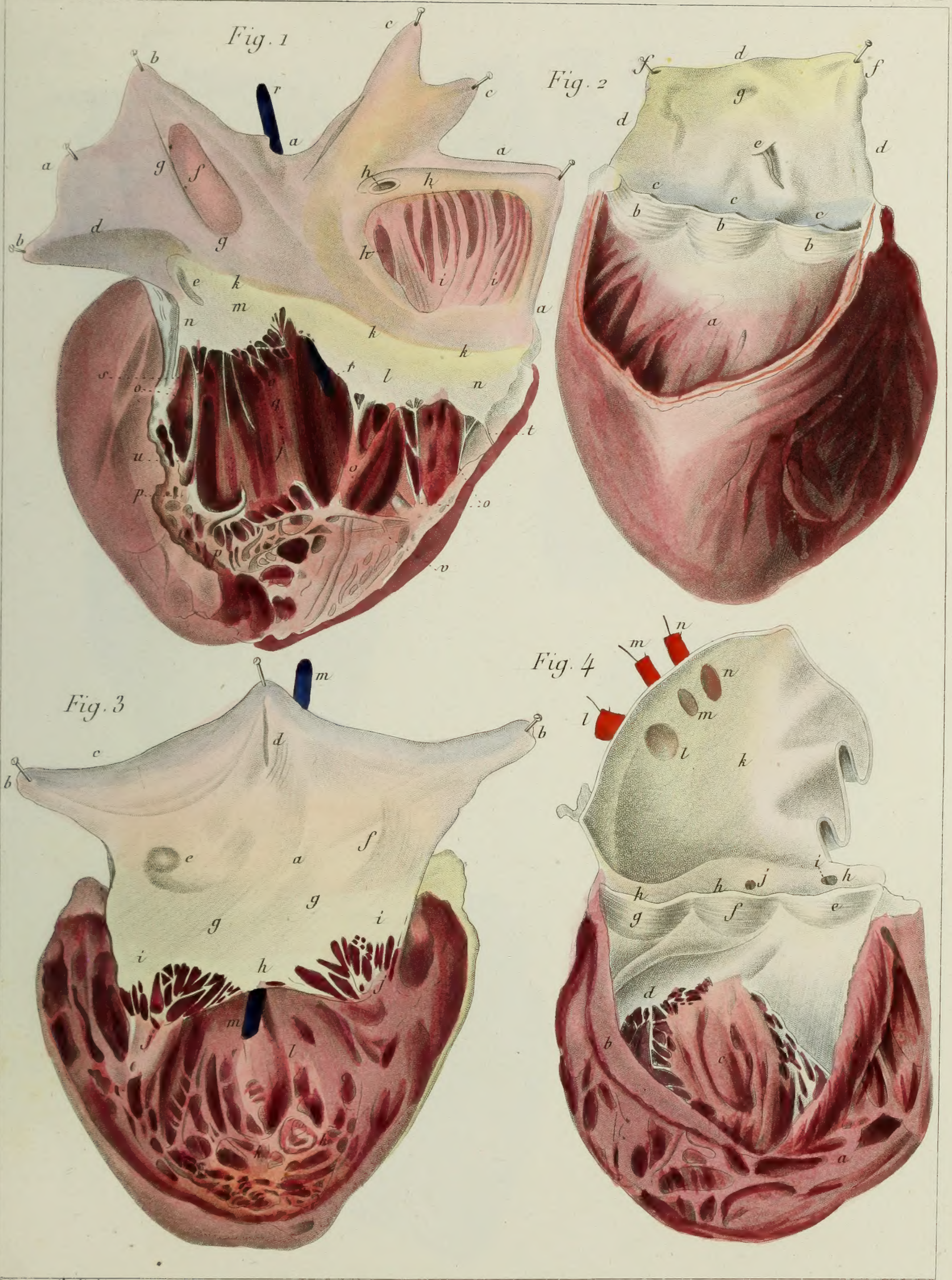

P. Duménil dir.t

STRUCTURE DU CŒUR

Fig. 1

Fig. 4

Fig. 2

Fig. 5

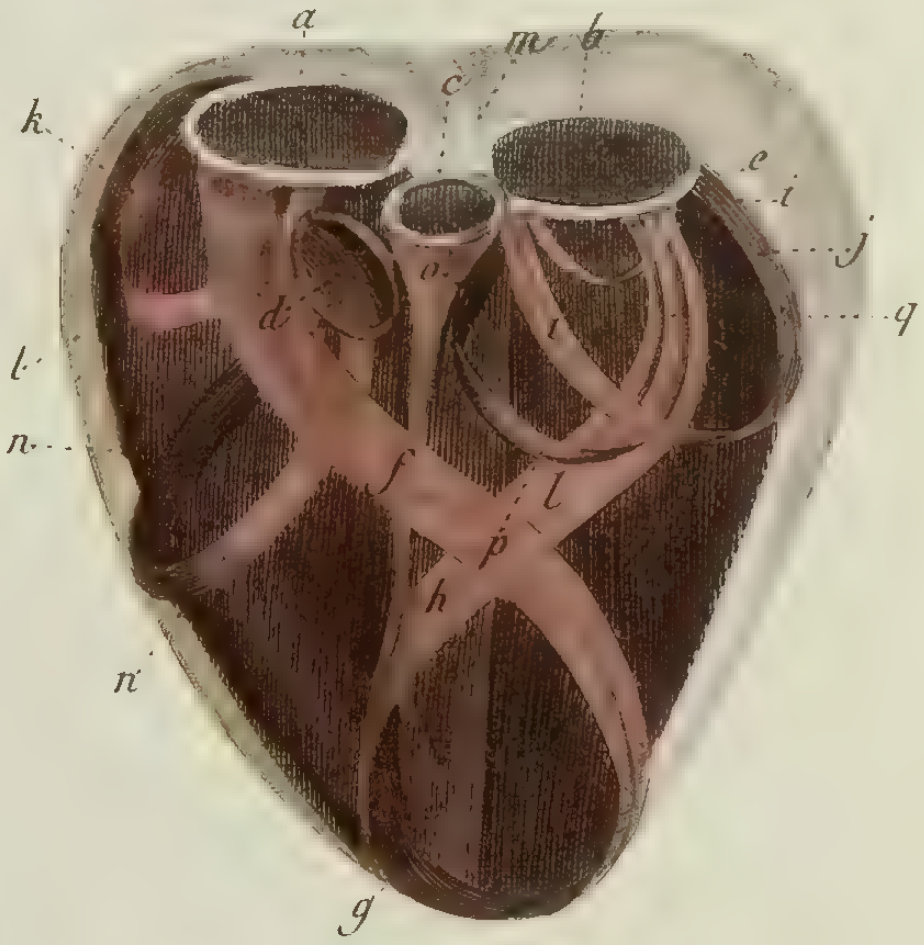

Fig. 3

Fig. 6



P Duménil Dir!

ORGANISATION DU CŒUR

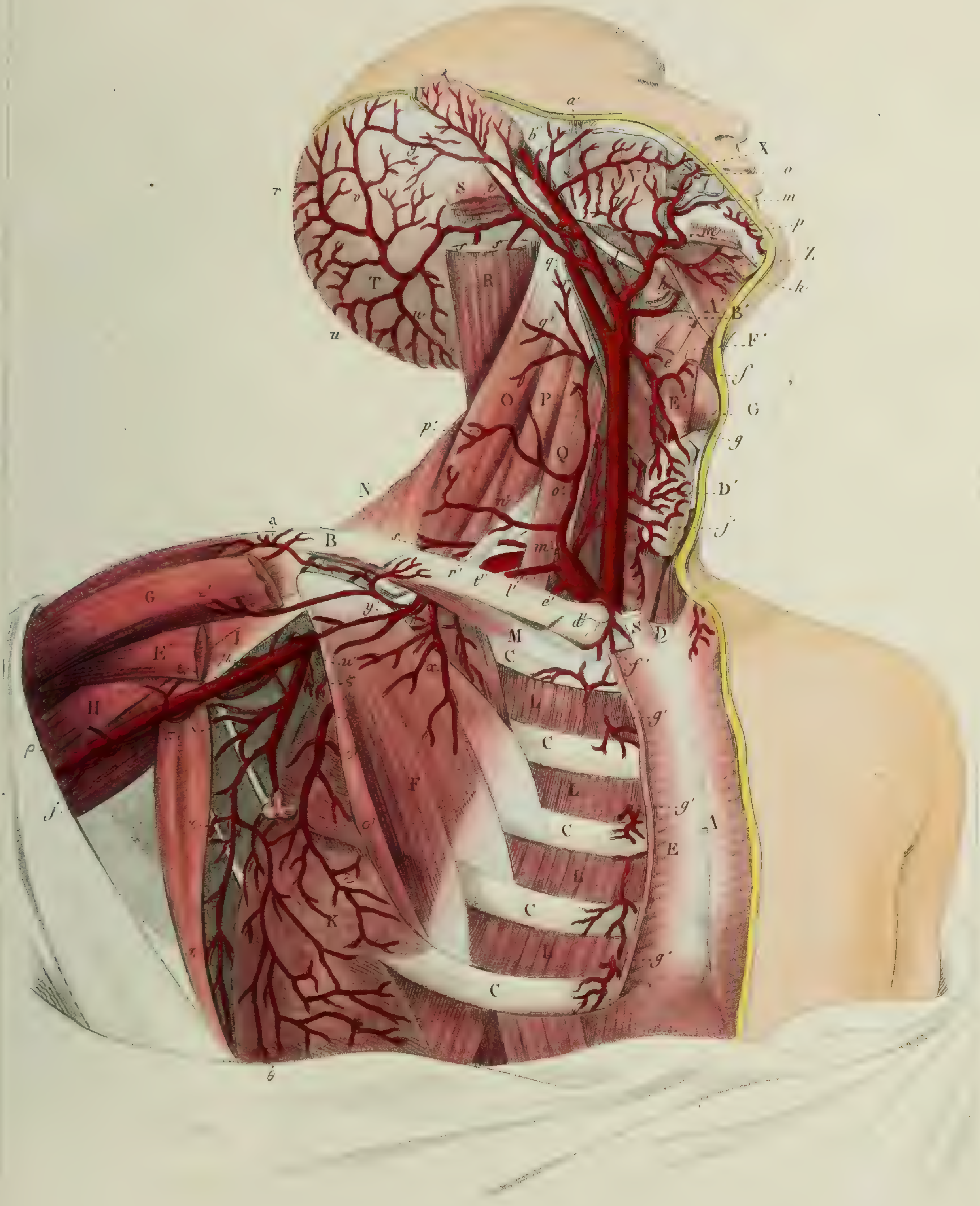

P. Duménil Dir.t

ARTÈRES CAROTIDE ET SOUS-CLAVIÈRE

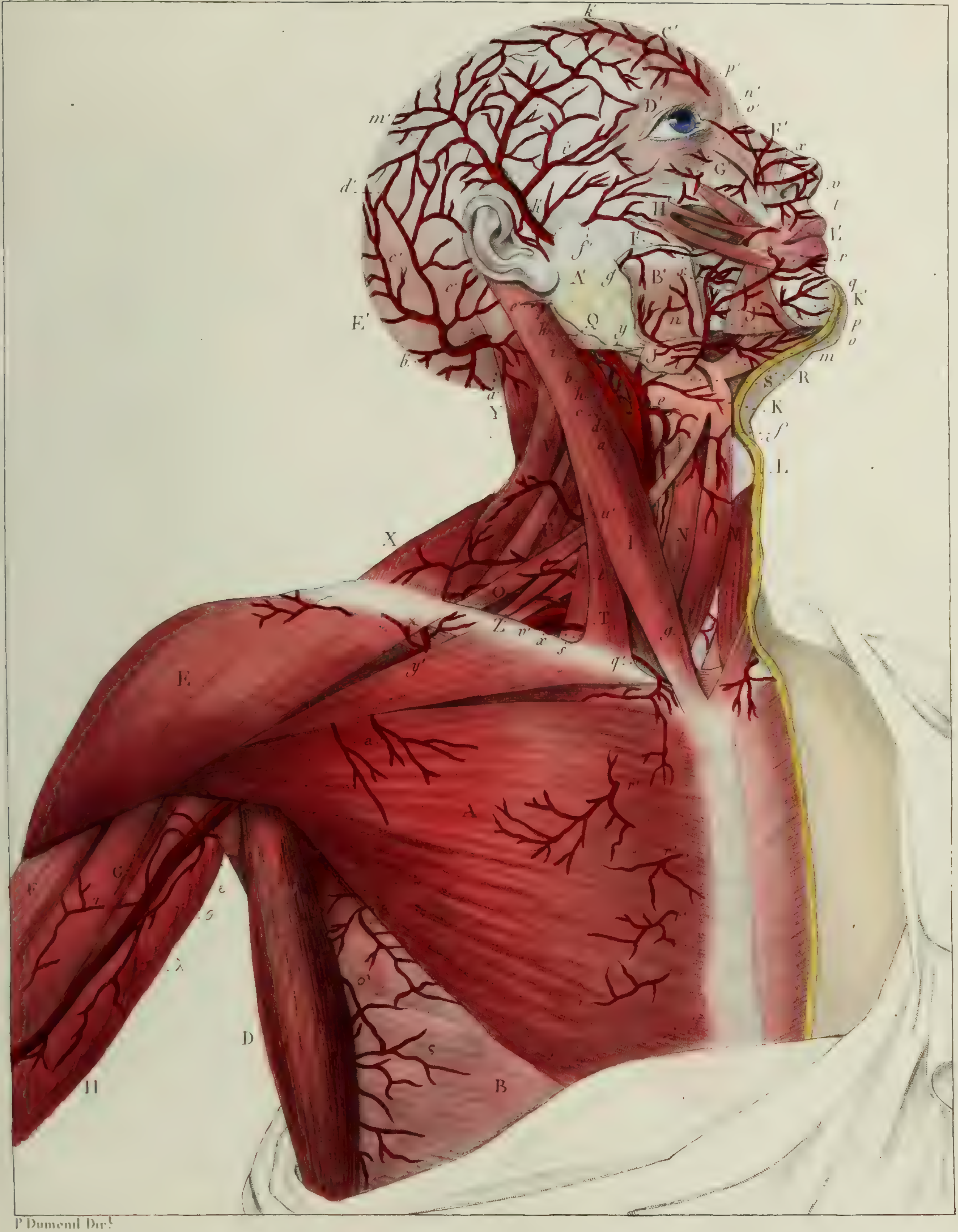

P Dumenil Dir.

ARTÈRES SUPERFICIELLES DE LA TÊTE ET DU COU.

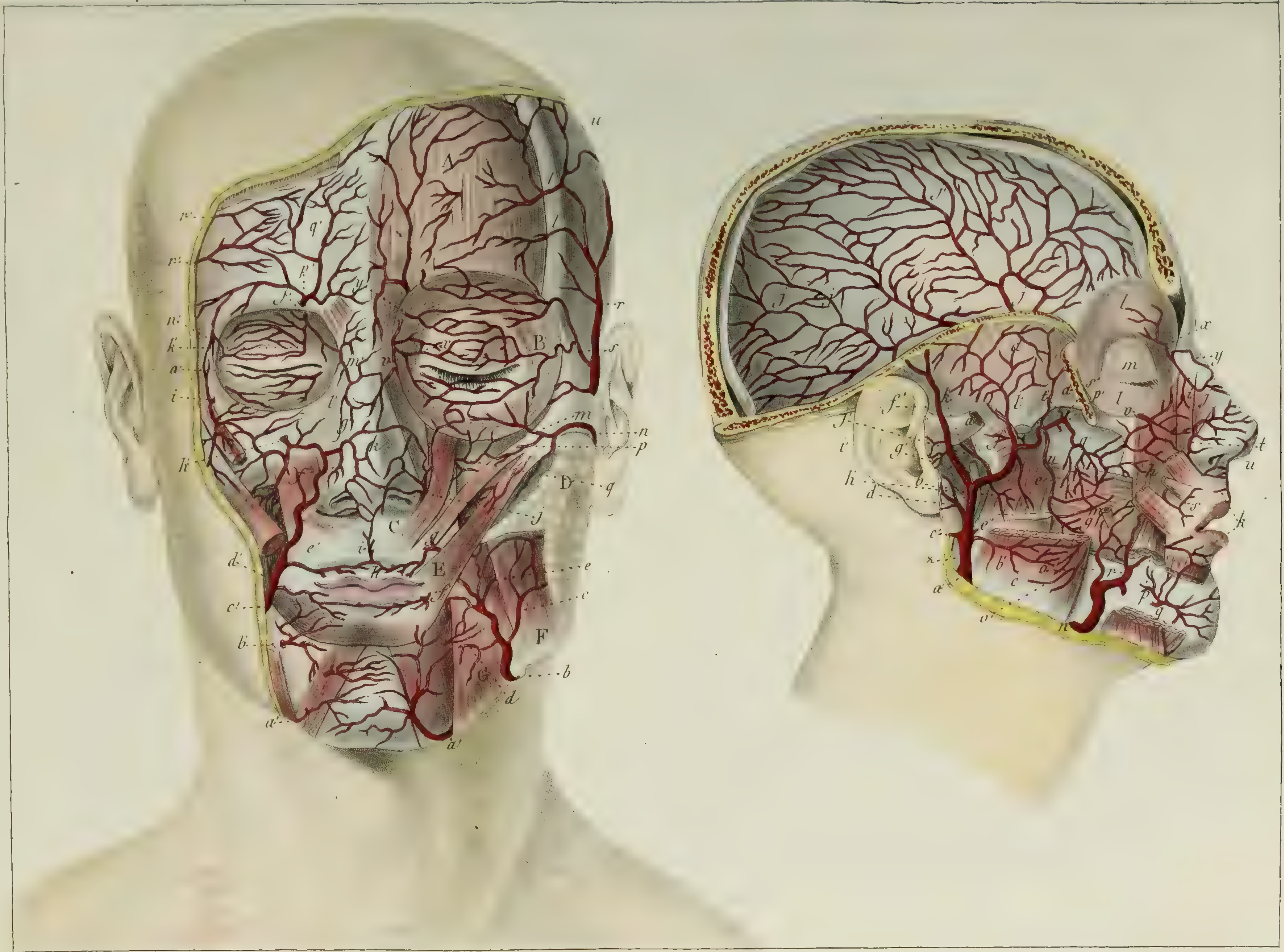

P Duménil Dir.

ARTÈRES MAXILLAIRES.

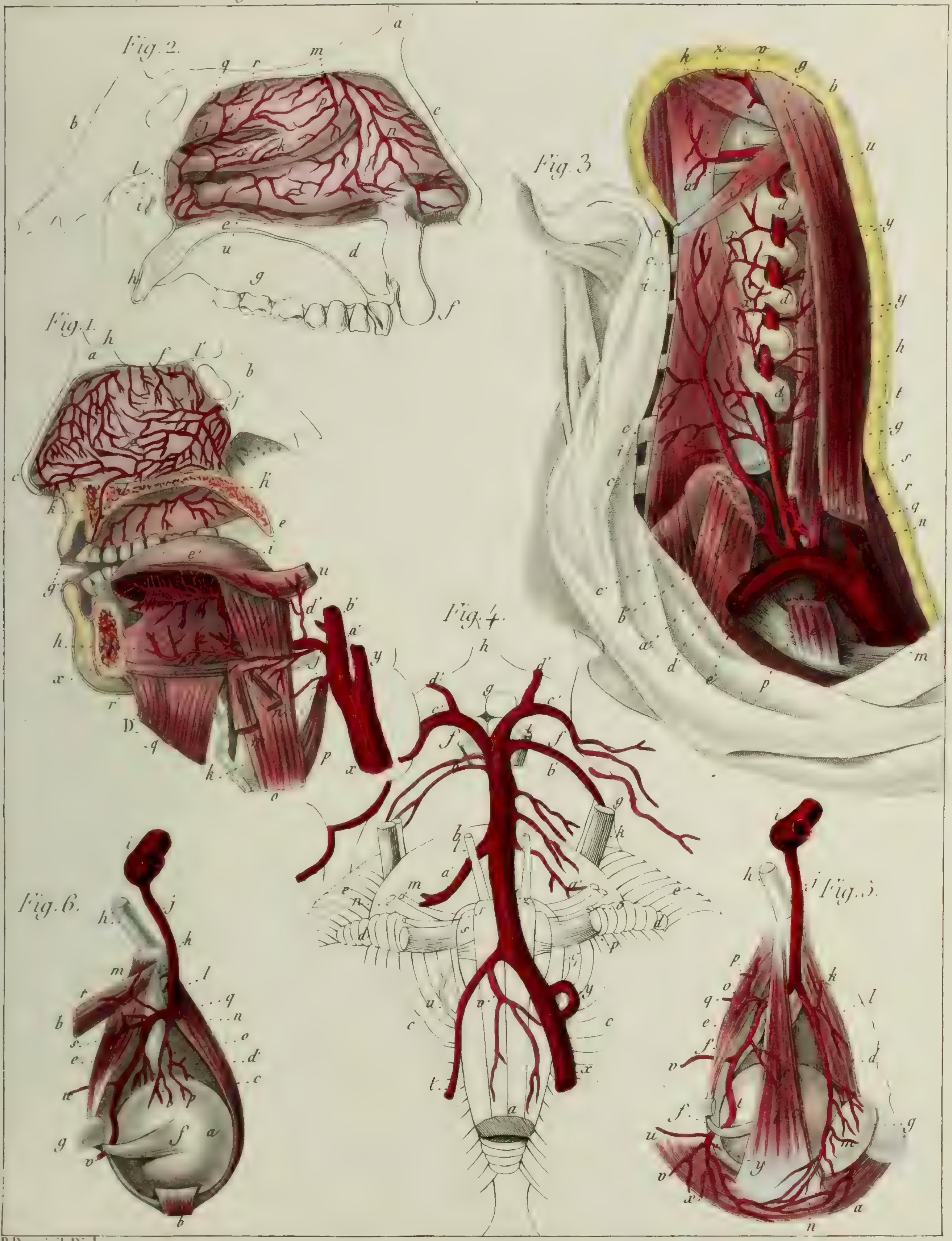

P Duménil Dir!

ARTÈRES NASALES, OPHTHALMIQUE ET VERTÉBRALE

Fig. 1

Fig. 2

P. Duménil dir.t

ARTÈRES ENCEPHALIQUES ARTÈRES INTECOSTALES

P Duménil Dir.

ARTÈRES DE L'ÉPAULE ET DU DOS.

P. Duménil Dir.t

ARTÈRES DU MEMBRE SUPÉRIEUR.

Fig. 1.

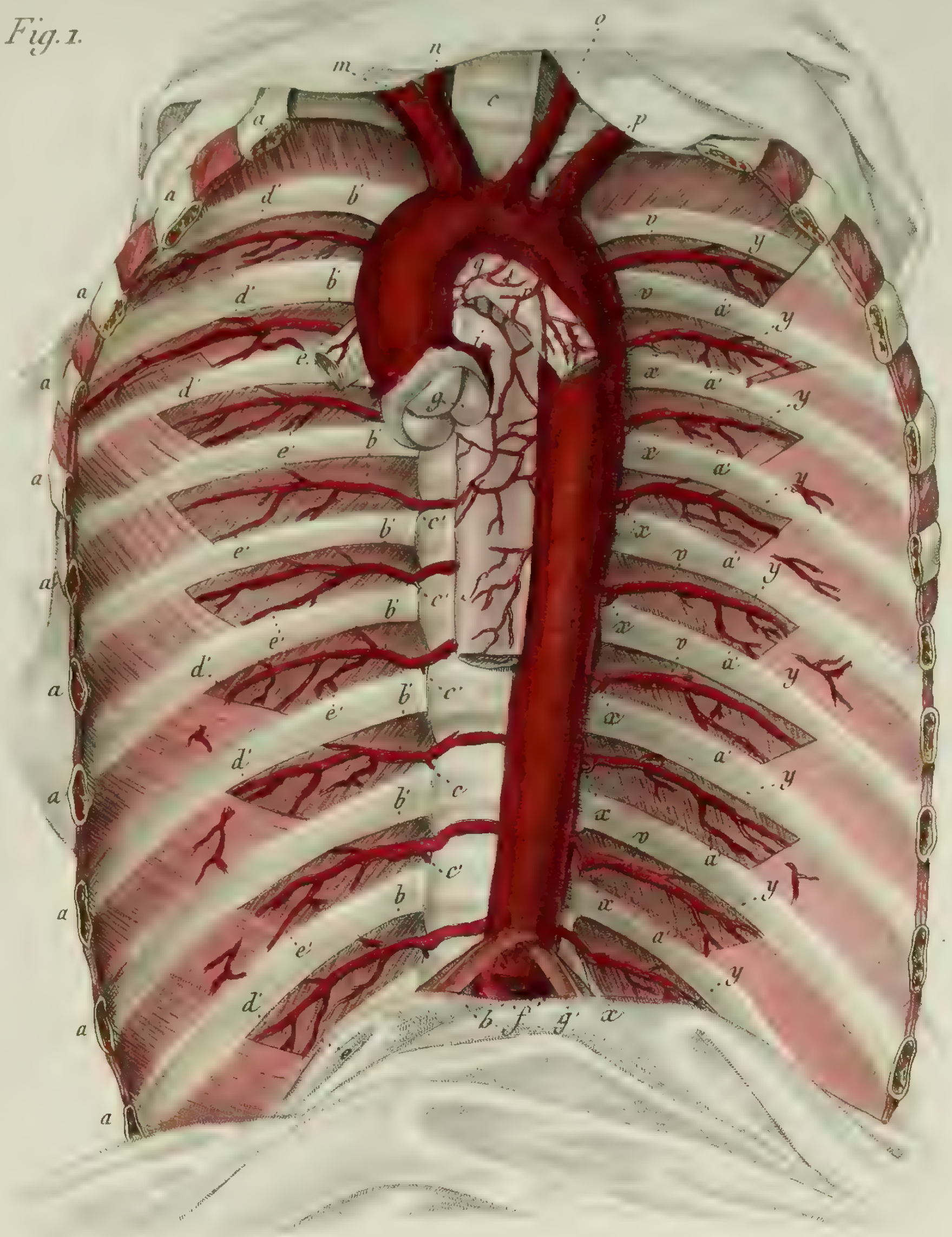

Fig. 2

P. Duménil Dir.t

ARTÈRE AORTE DESCENDANTE

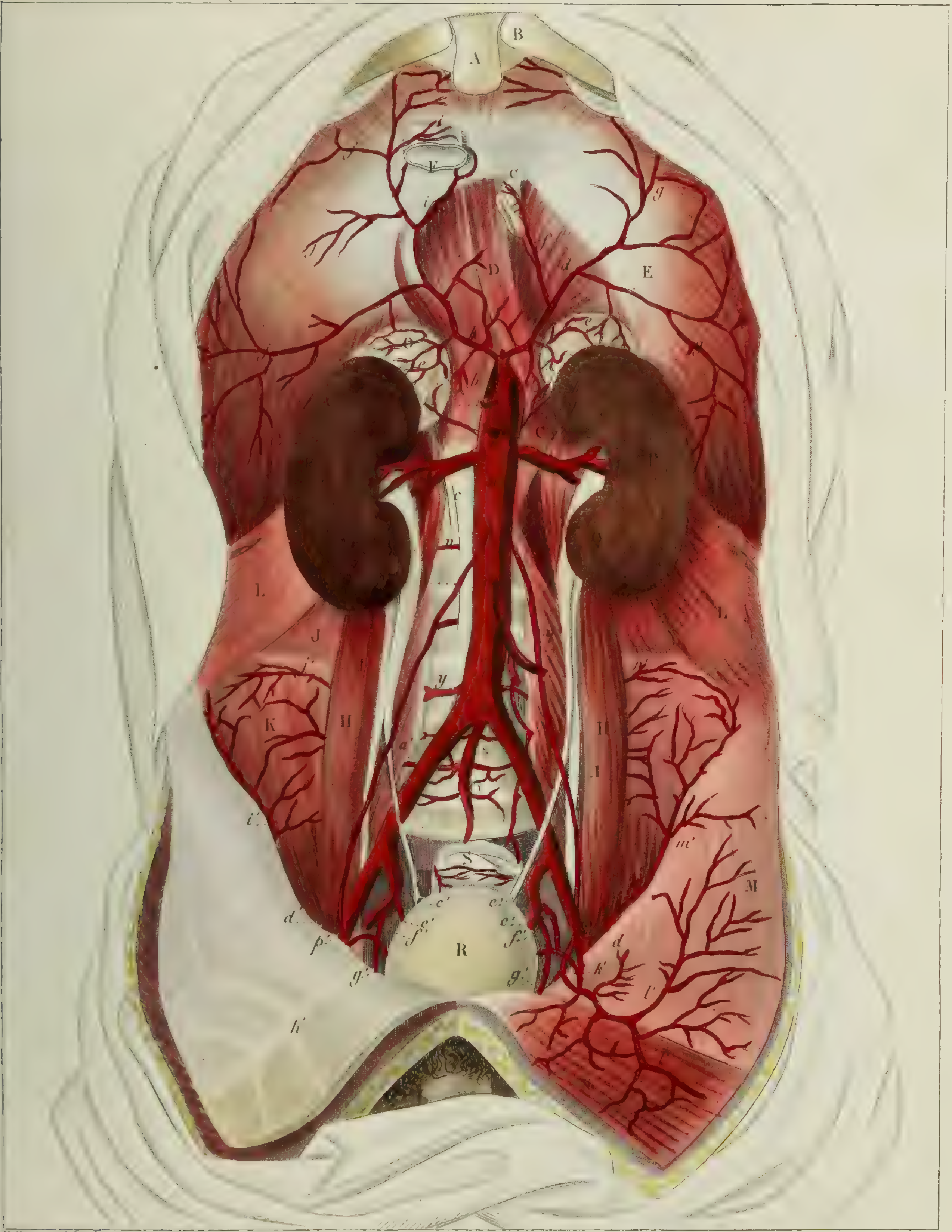

P. Duménil Dir.

AORTE ABDOMINALE.

Fig. 1.

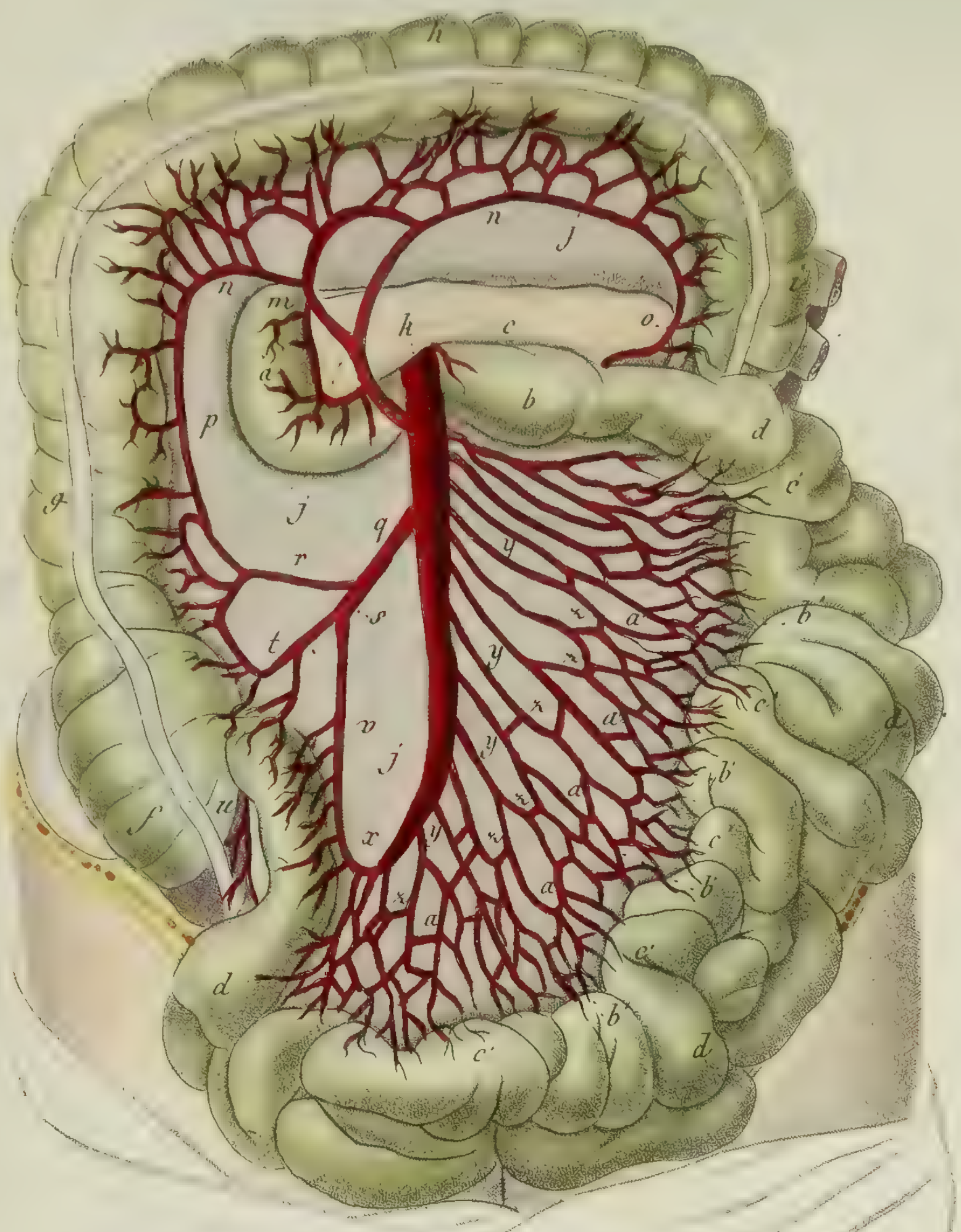

Fig. 2.

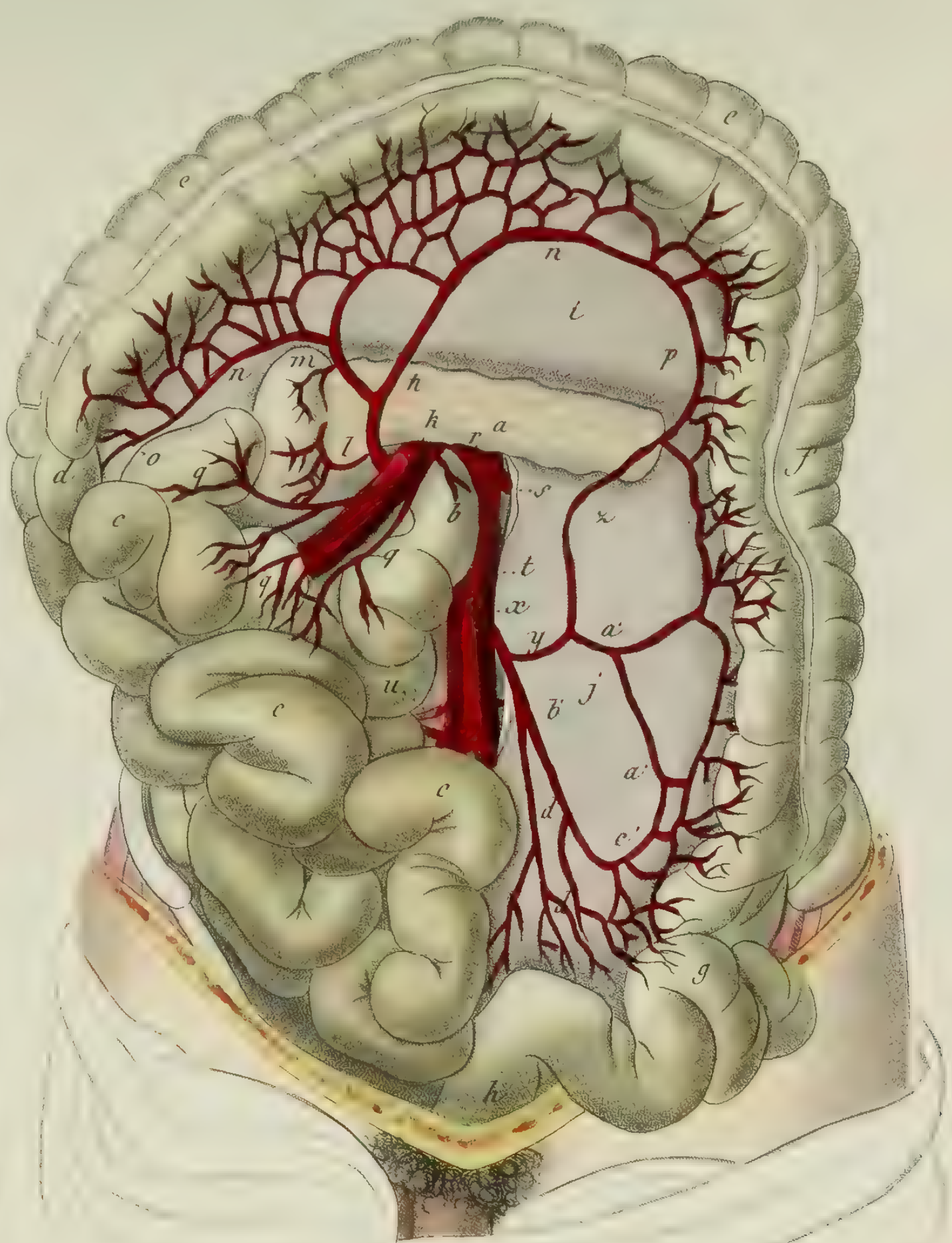

P. Duménil Dir.t

ARTÈRES MESENTERIQUES.

Fig. 3.

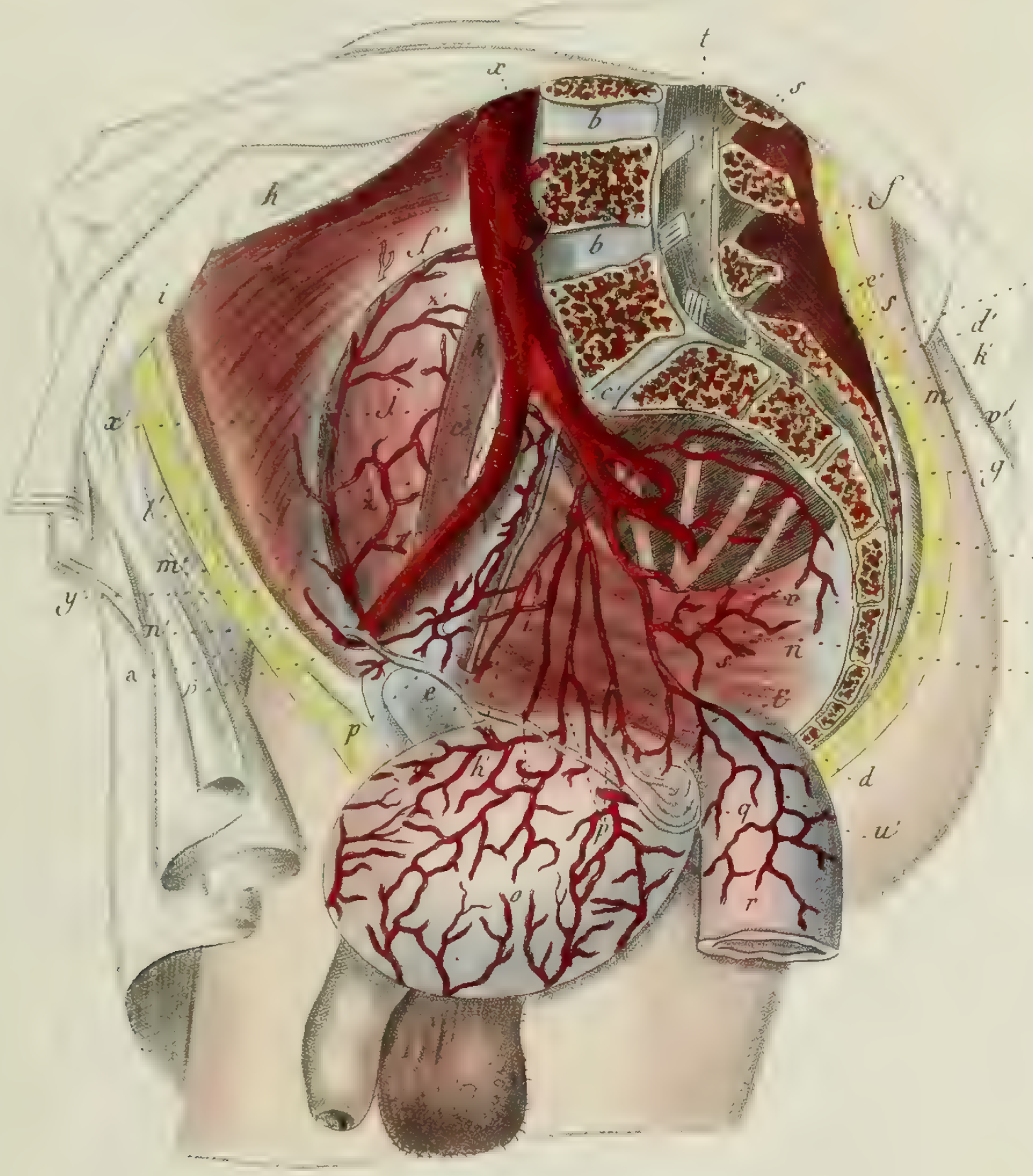

Fig. 2.

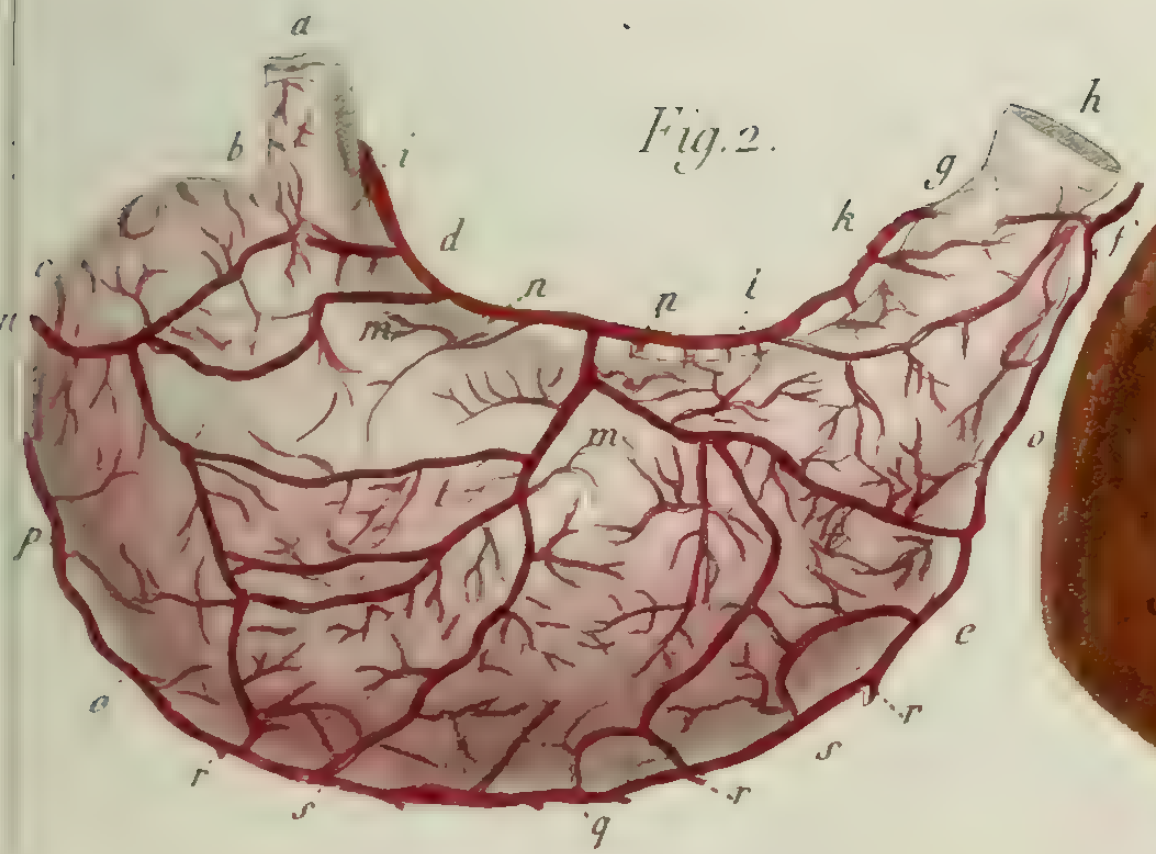

Fig. 1.

P. Duménil Dir.t

ARTÈRES CŒLIAQUE ET HYPOGASTRIQUE.

Fig. 2

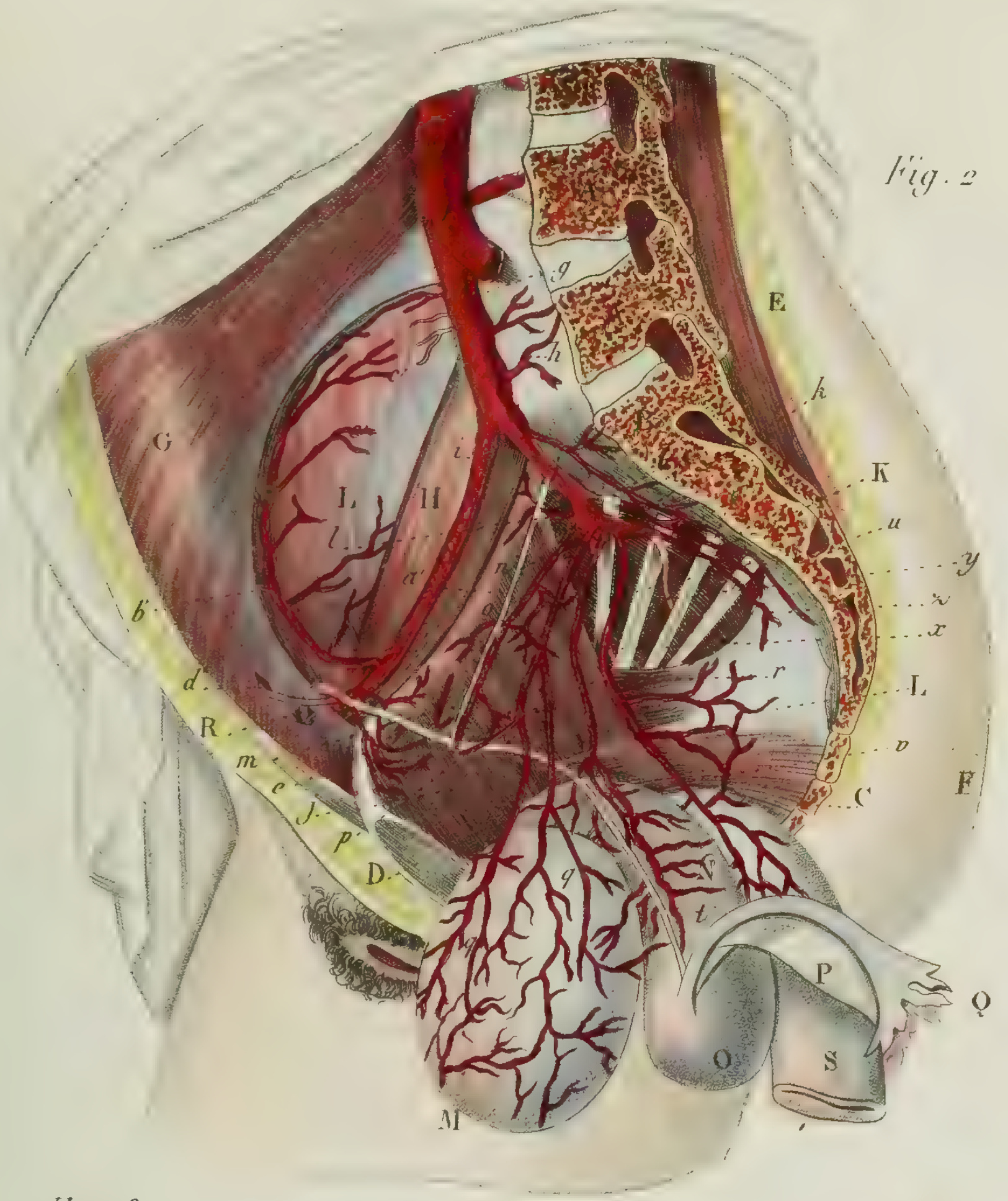

Fig. 3

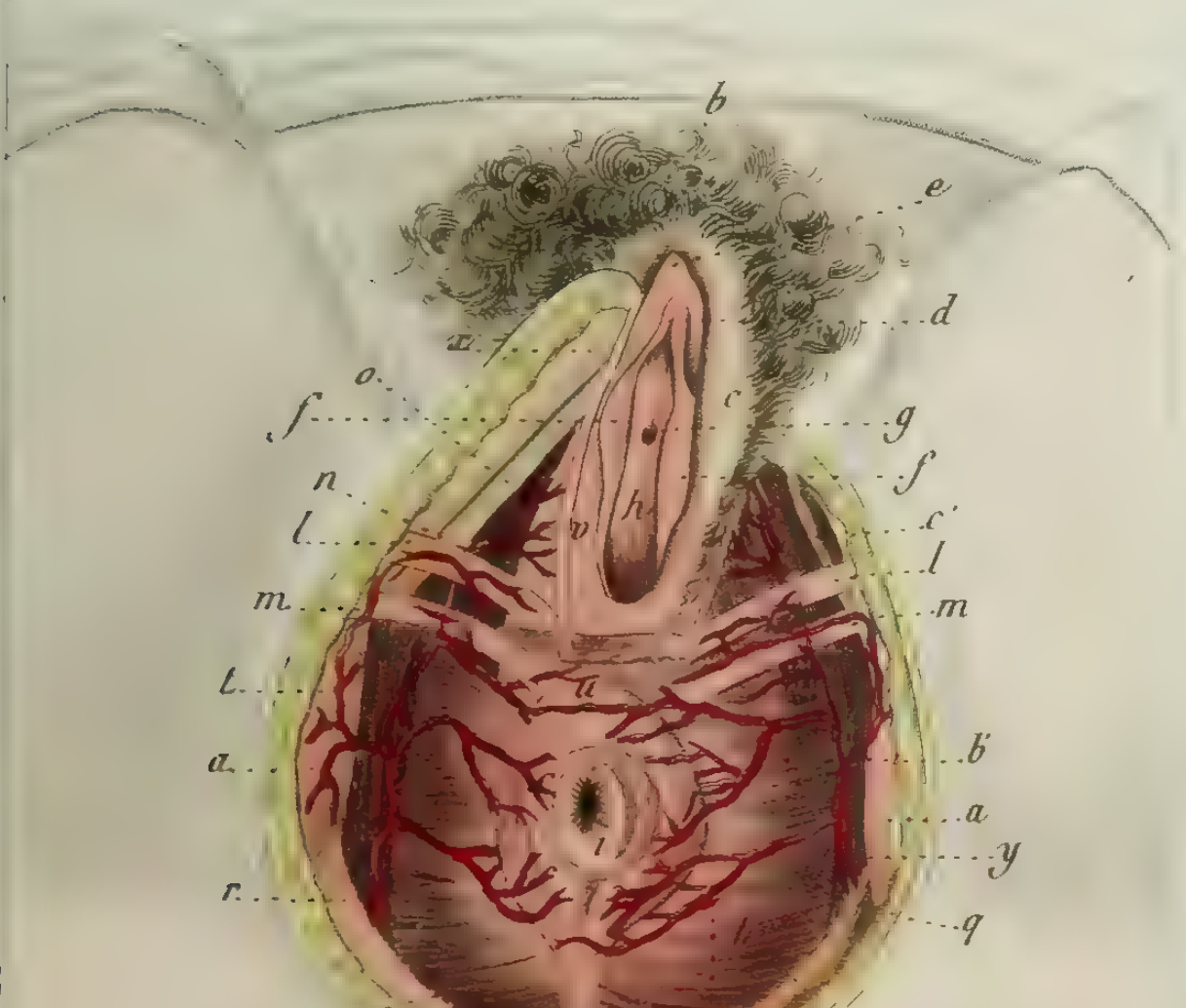

Fig. 1

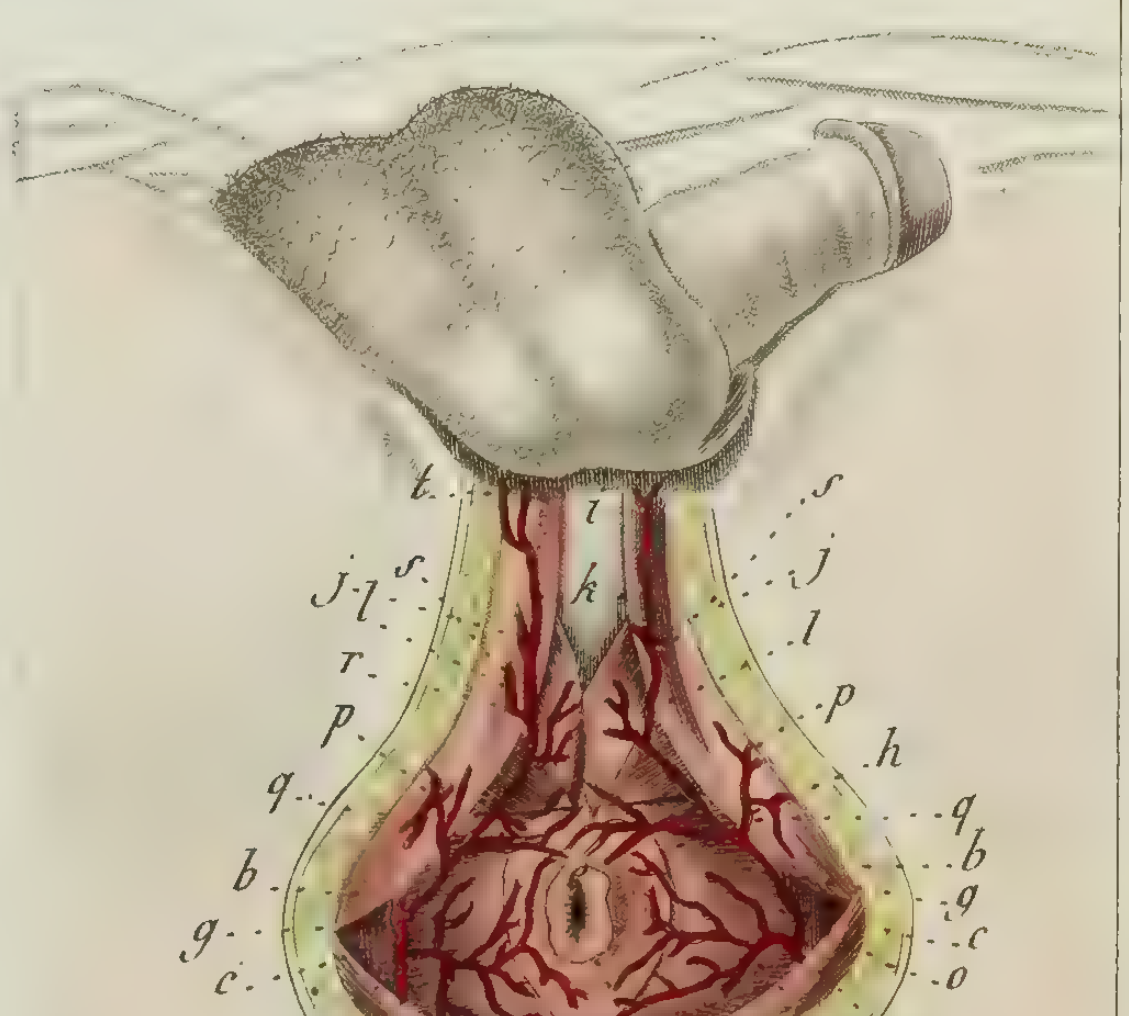

P. Dumenil Dir.t

ARTÈRE HYPOGASTRIQUE.

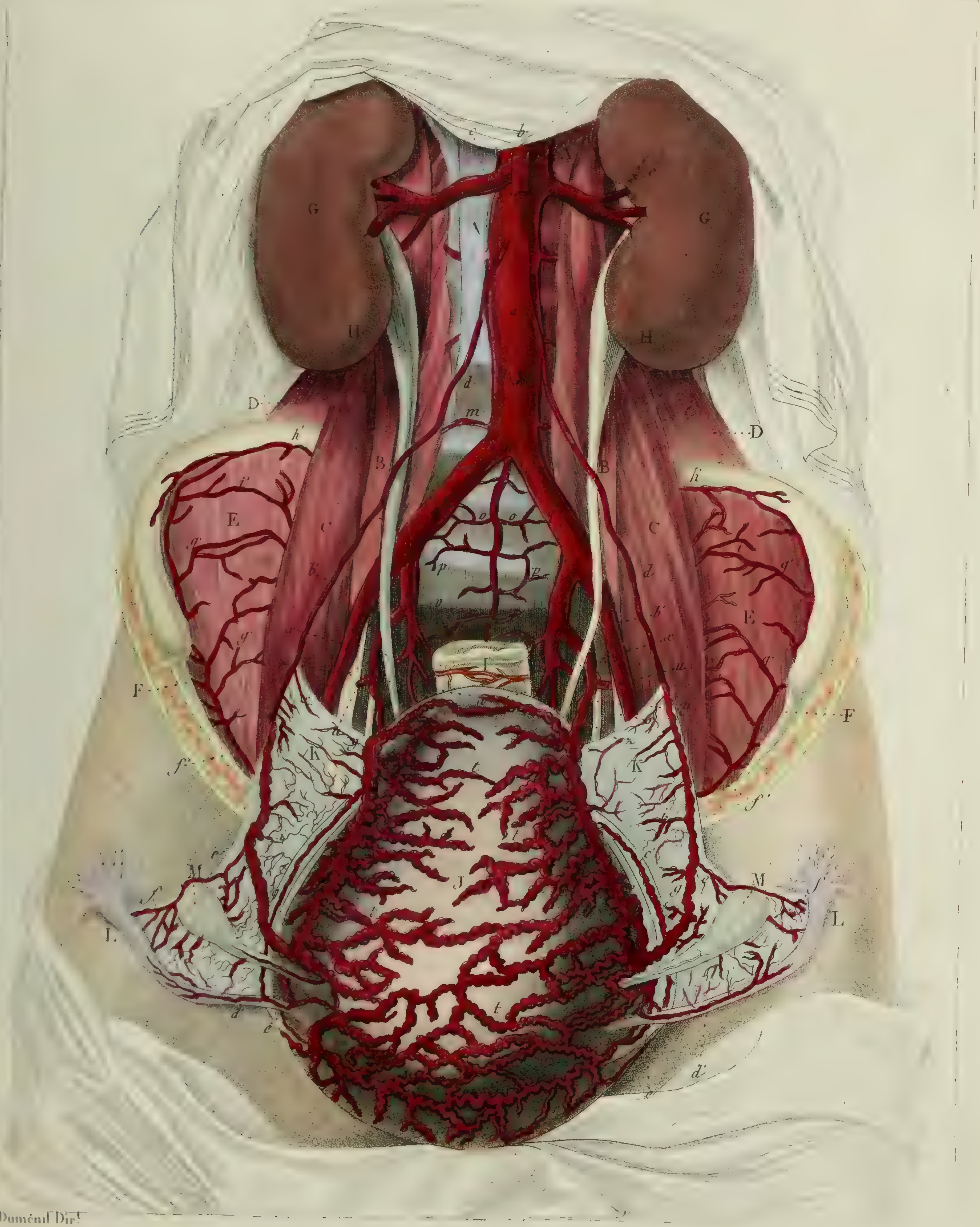

P Duménil Dir.t

ARTÈRES UTÉRINES.

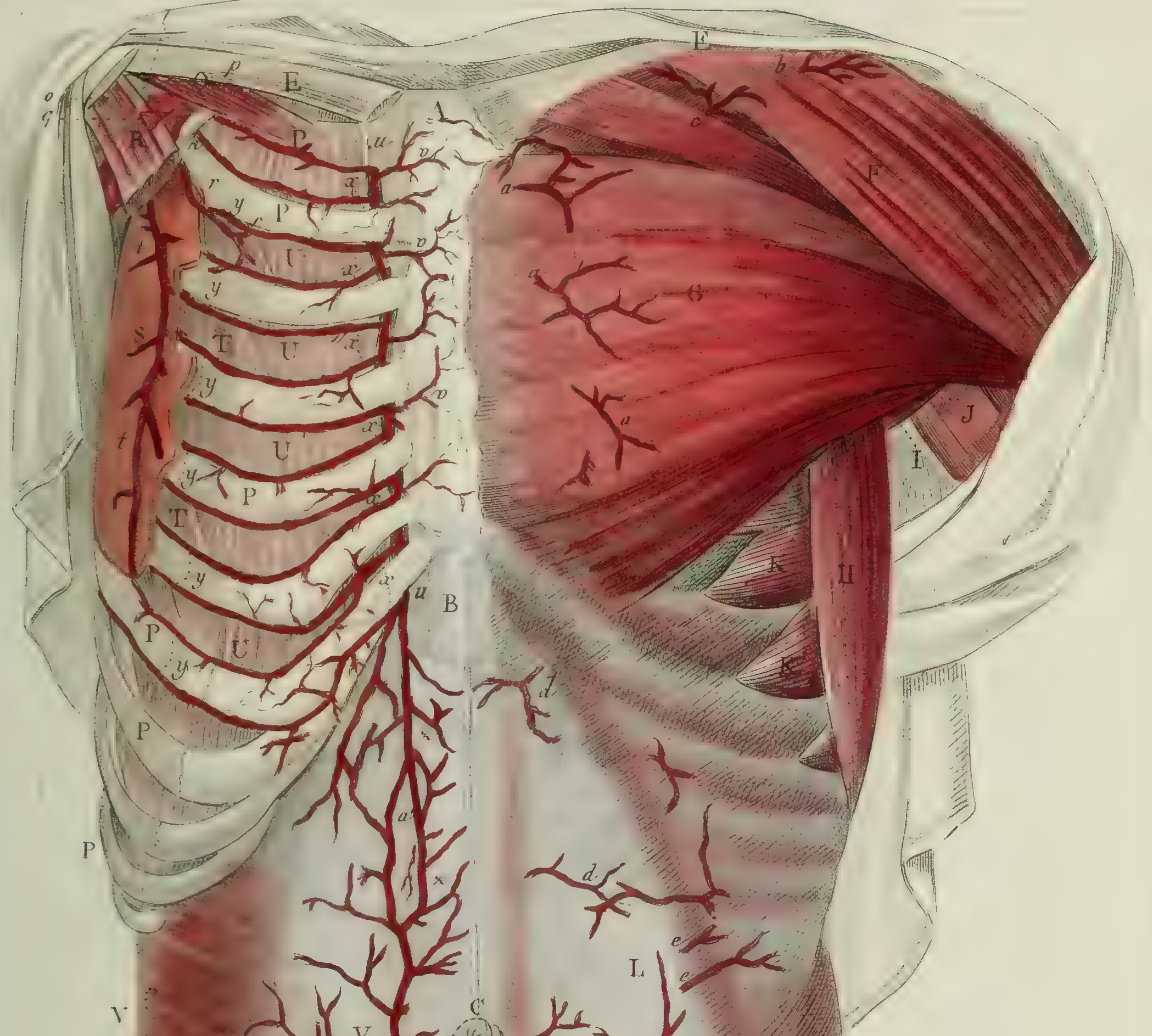

P Dumenil Dir.t

ARTÈRES MAMMAIRE INTERNE ET ÉPIGASTRIQUES

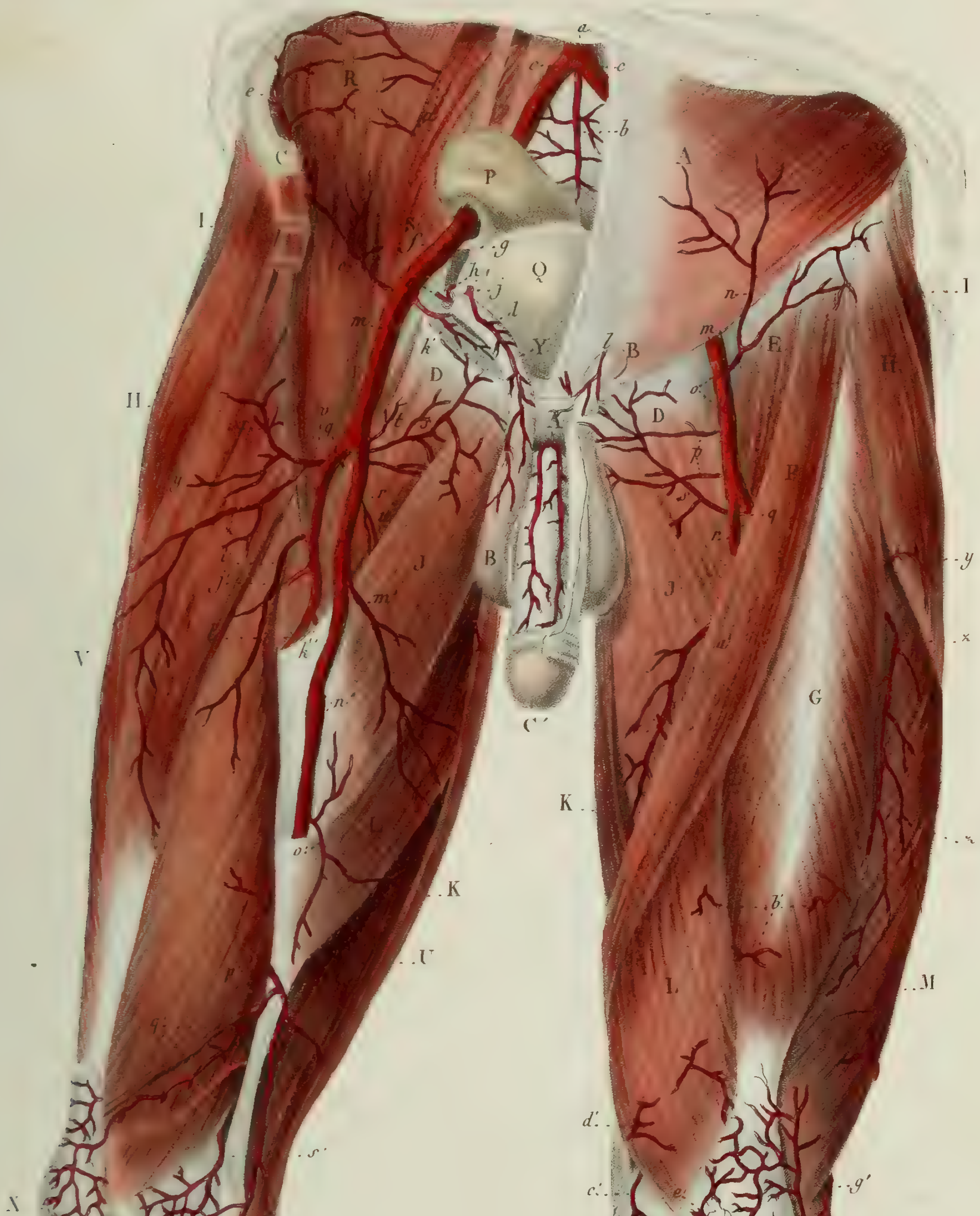

P Duménil Dir!

ARTÈRE CRURALE.

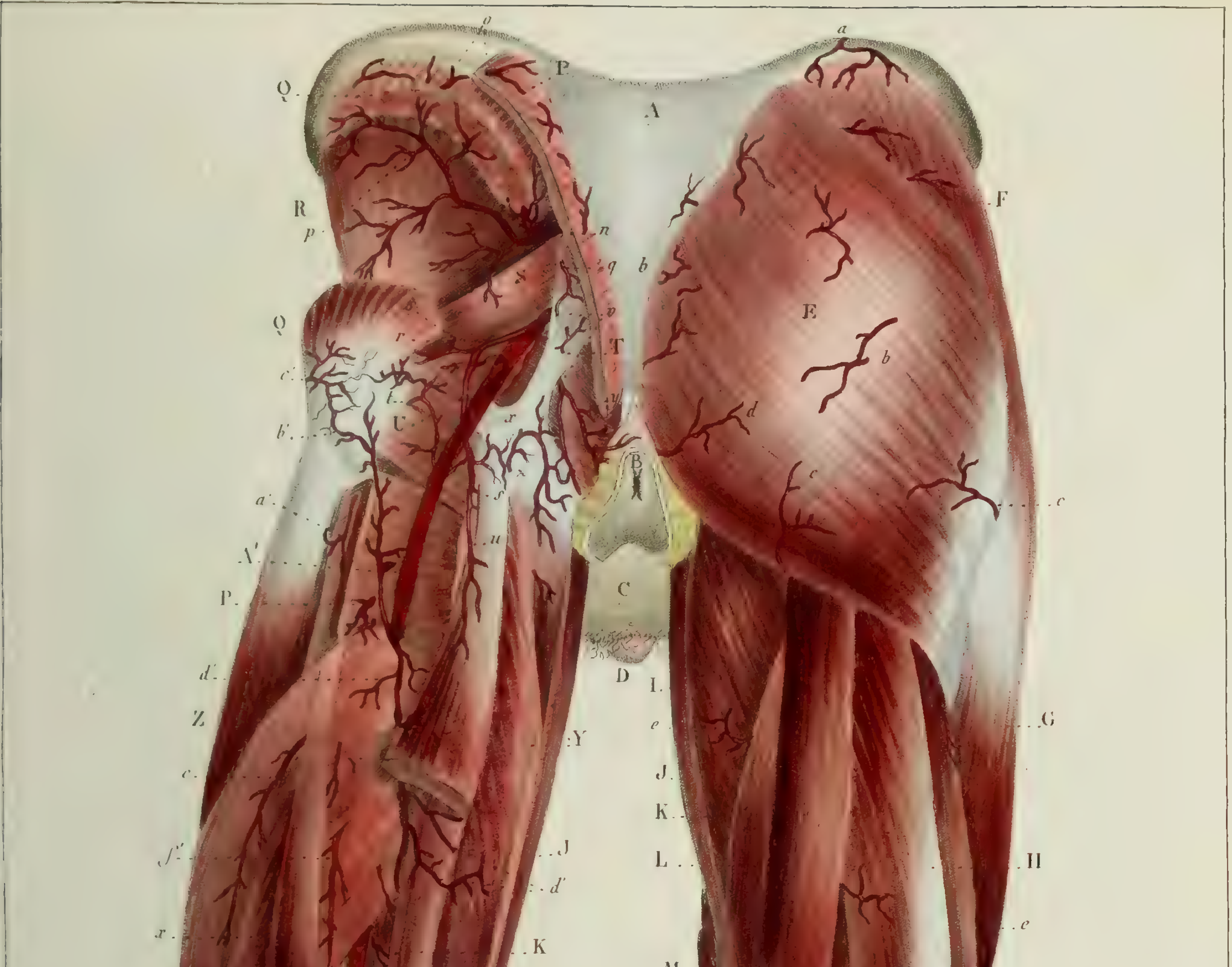

P. Duménil Dir!

ARTÈRES DE LA CUISSE.

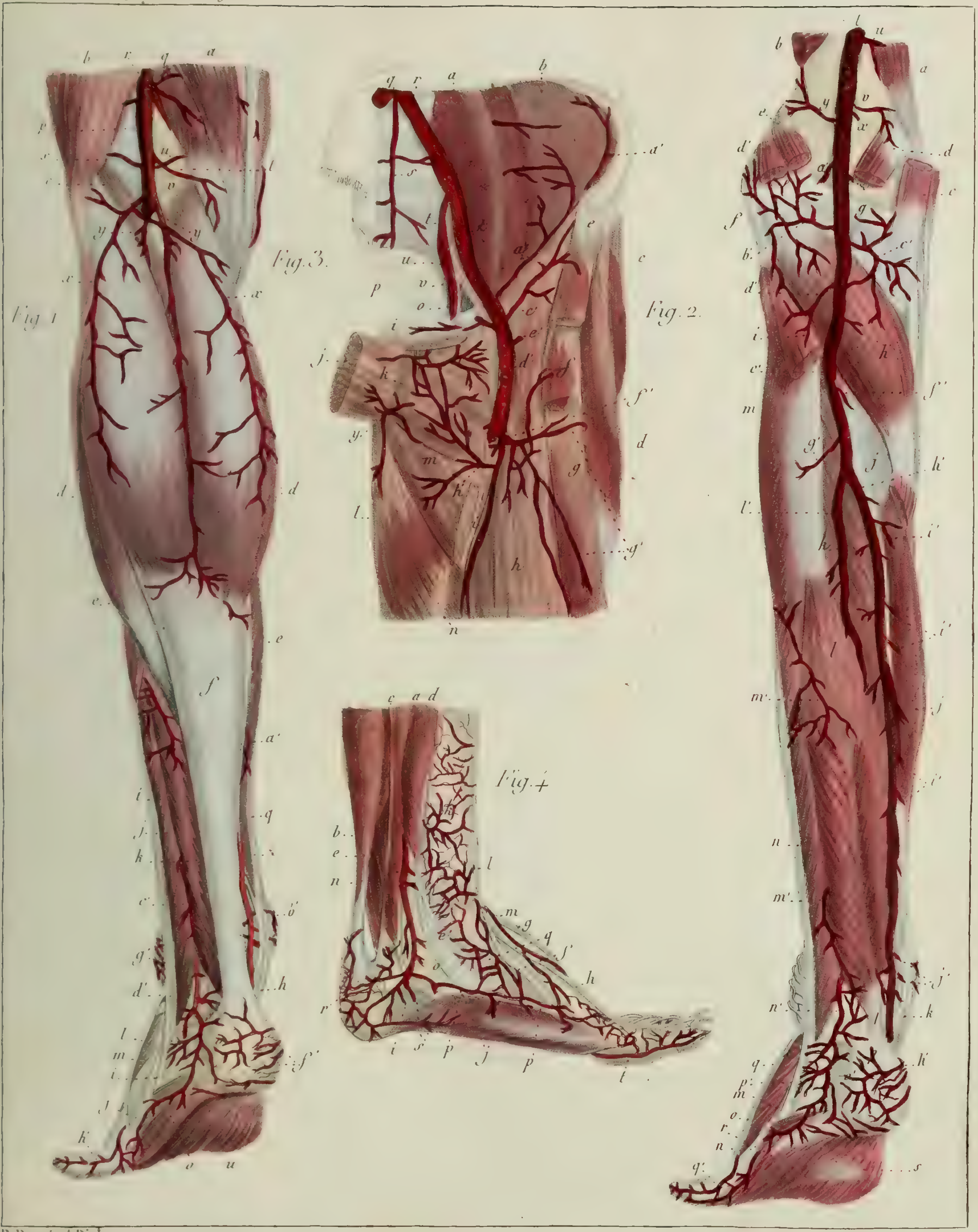

P. Duménil Dir!

ARTÈRES DE LA JAMBE

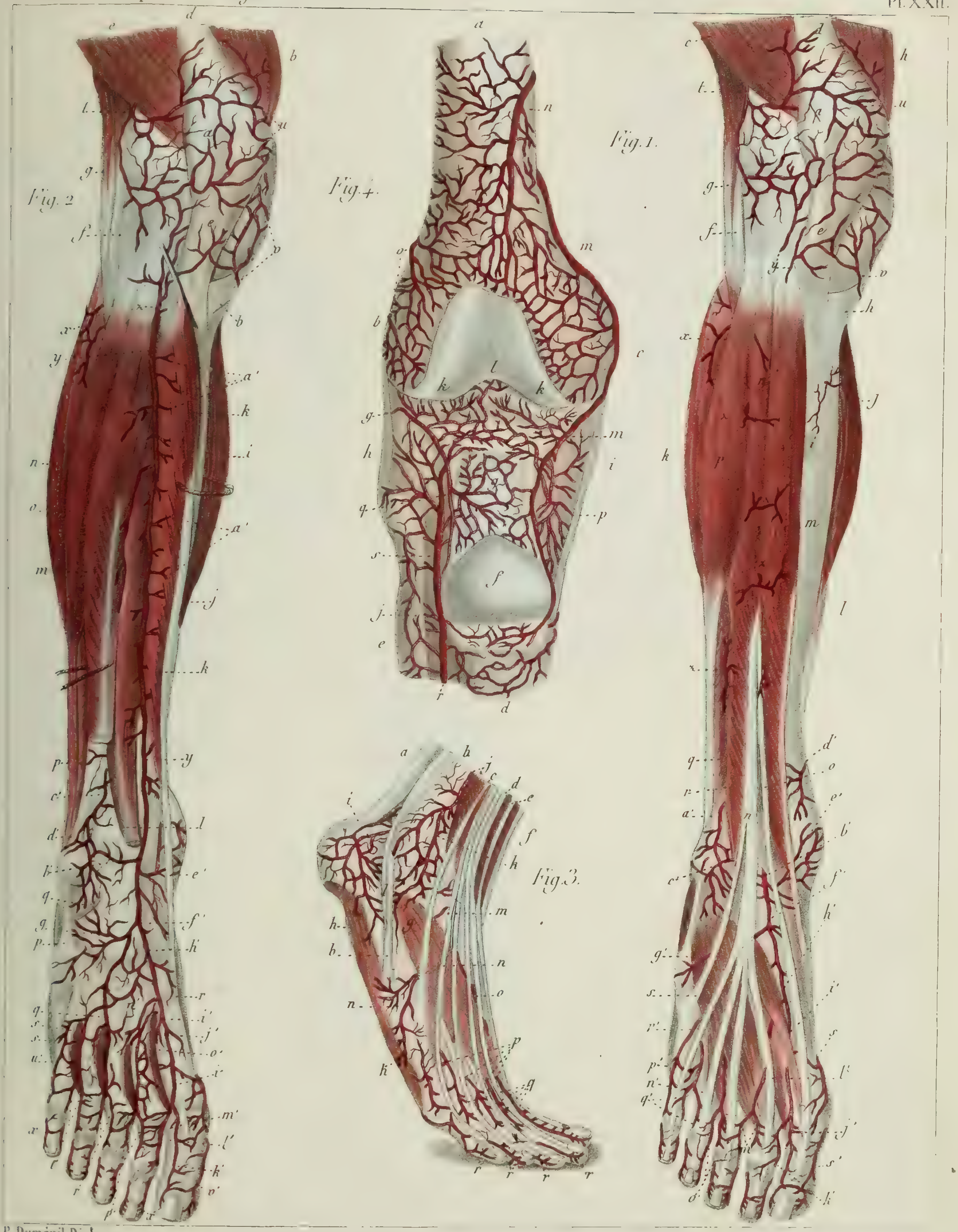

P. Duménil Dir.

ARTÈRES DE LA JAMBE ET DU PIED.

Fig. 1.

Fig. 2.

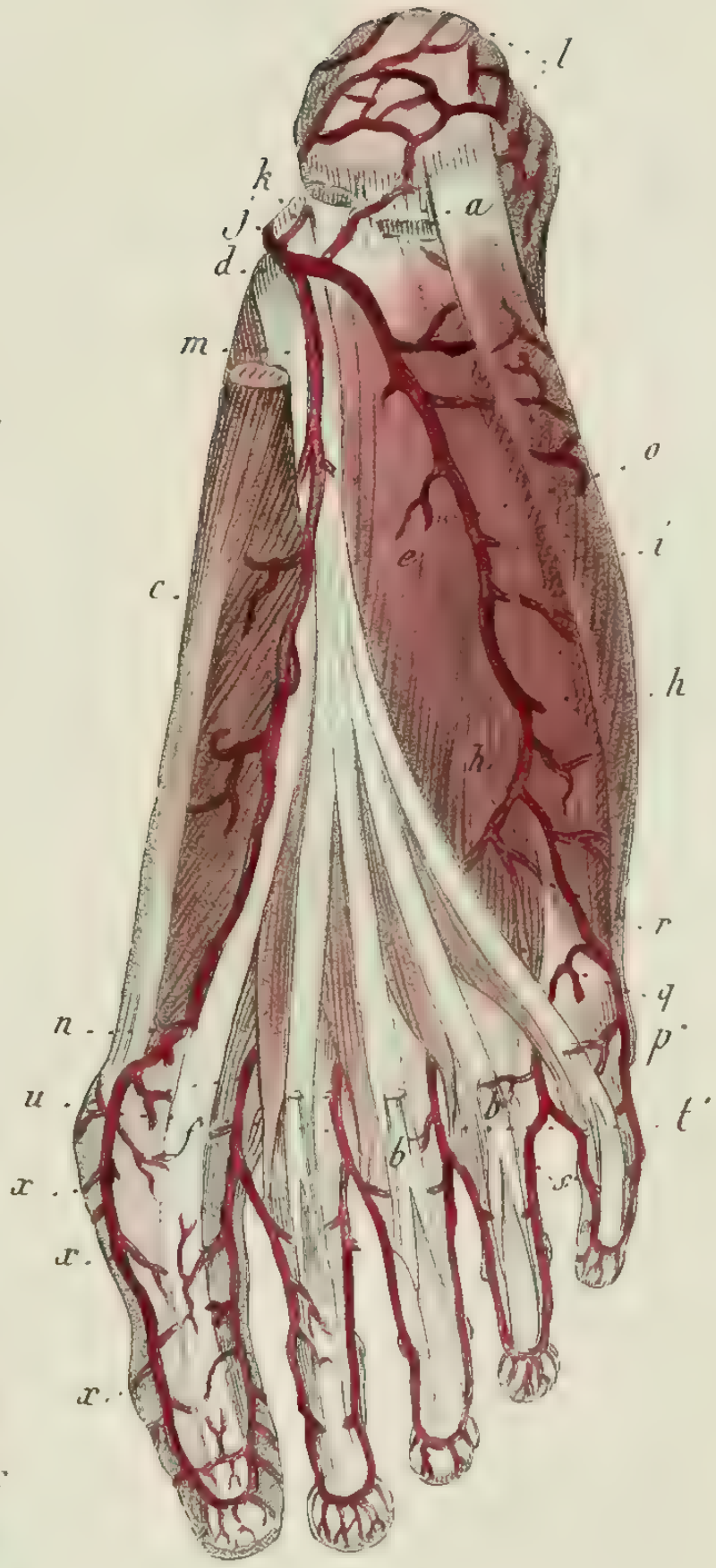

Fig. 3.

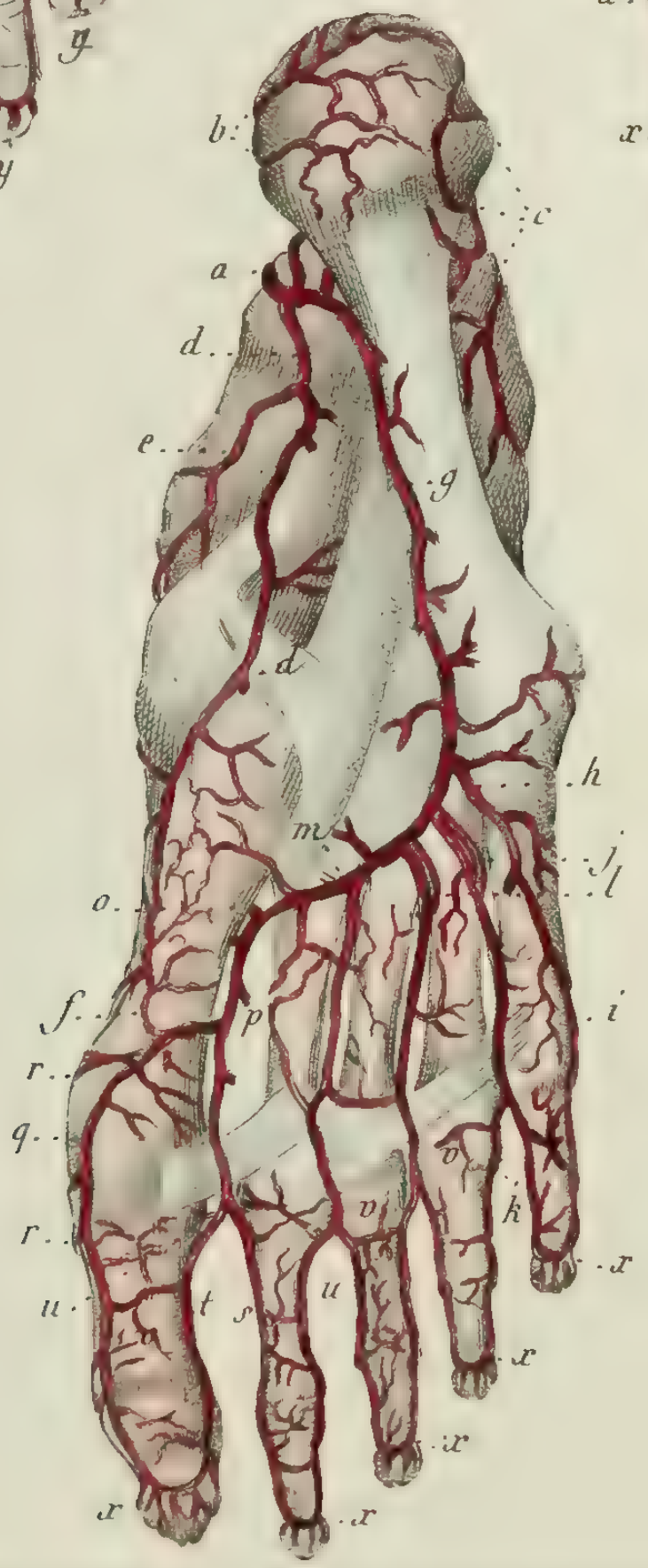

P. Duménil Dir.t

ARTÈRES PLANTAIRES

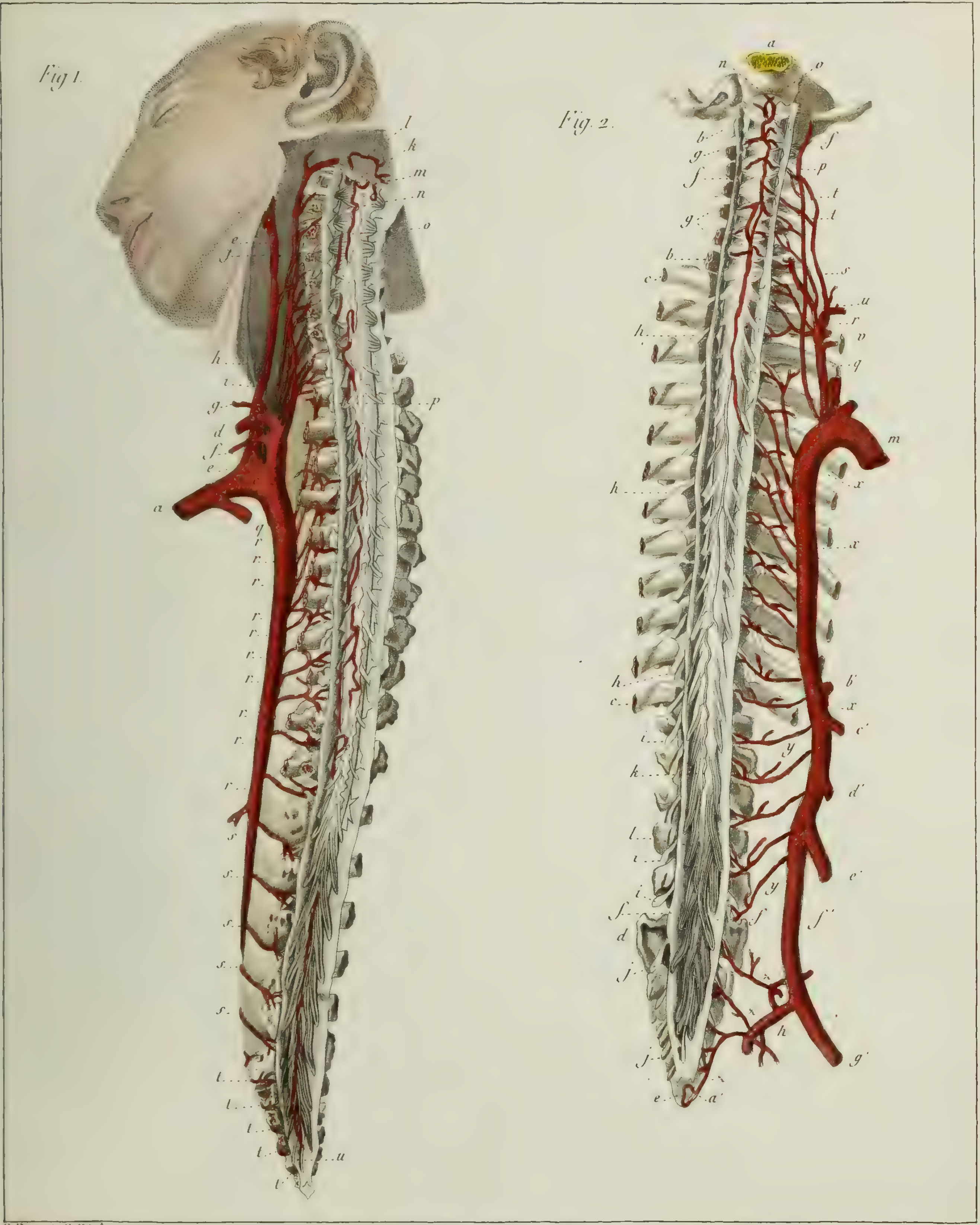

P. Duménil Dir.

ARTÈRES DE LA MOELLE ÉPINIÈRE

P. Dumenil Dir.

VEINES SUPERFICIELLES DE LA TÊTE ET DU COU.

P. Dumenil Dir.

VEINES PROFONDES DE LA TÊTE ET DU COU.

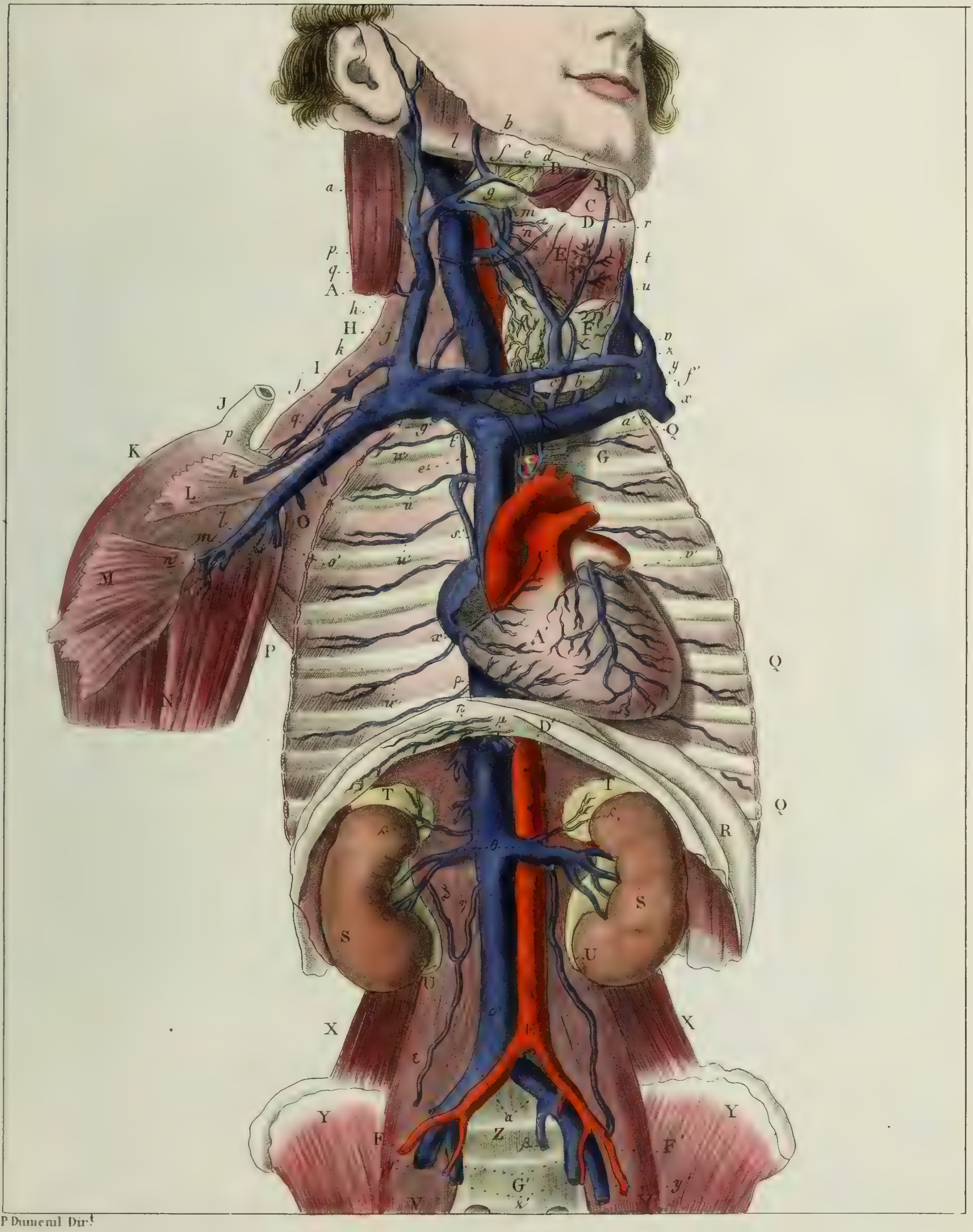

P. Dumenil Dir.t

VEINES CAVES

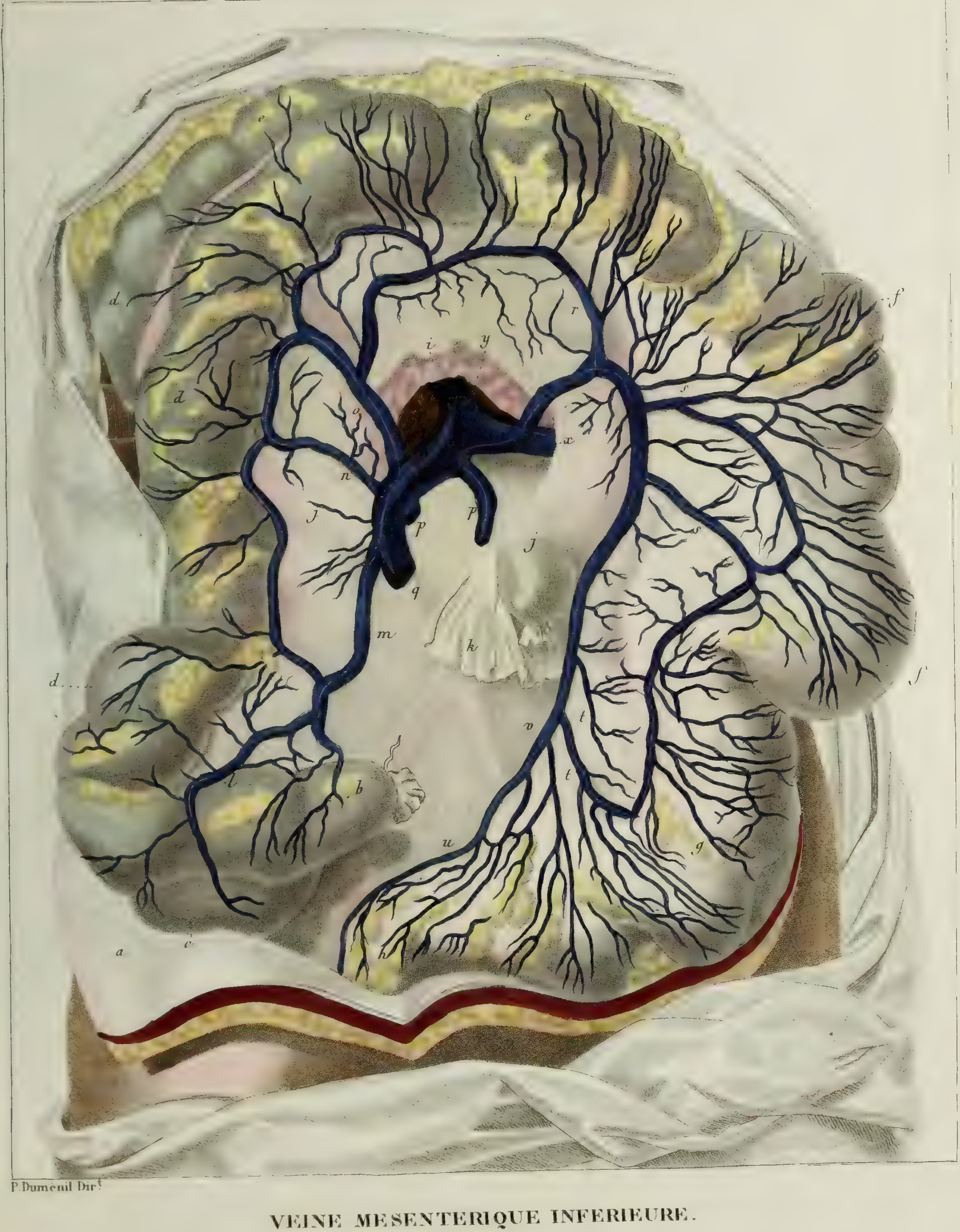

P. Duménil Dir.

VEINE MESENTERIQUE INFERIEURE.

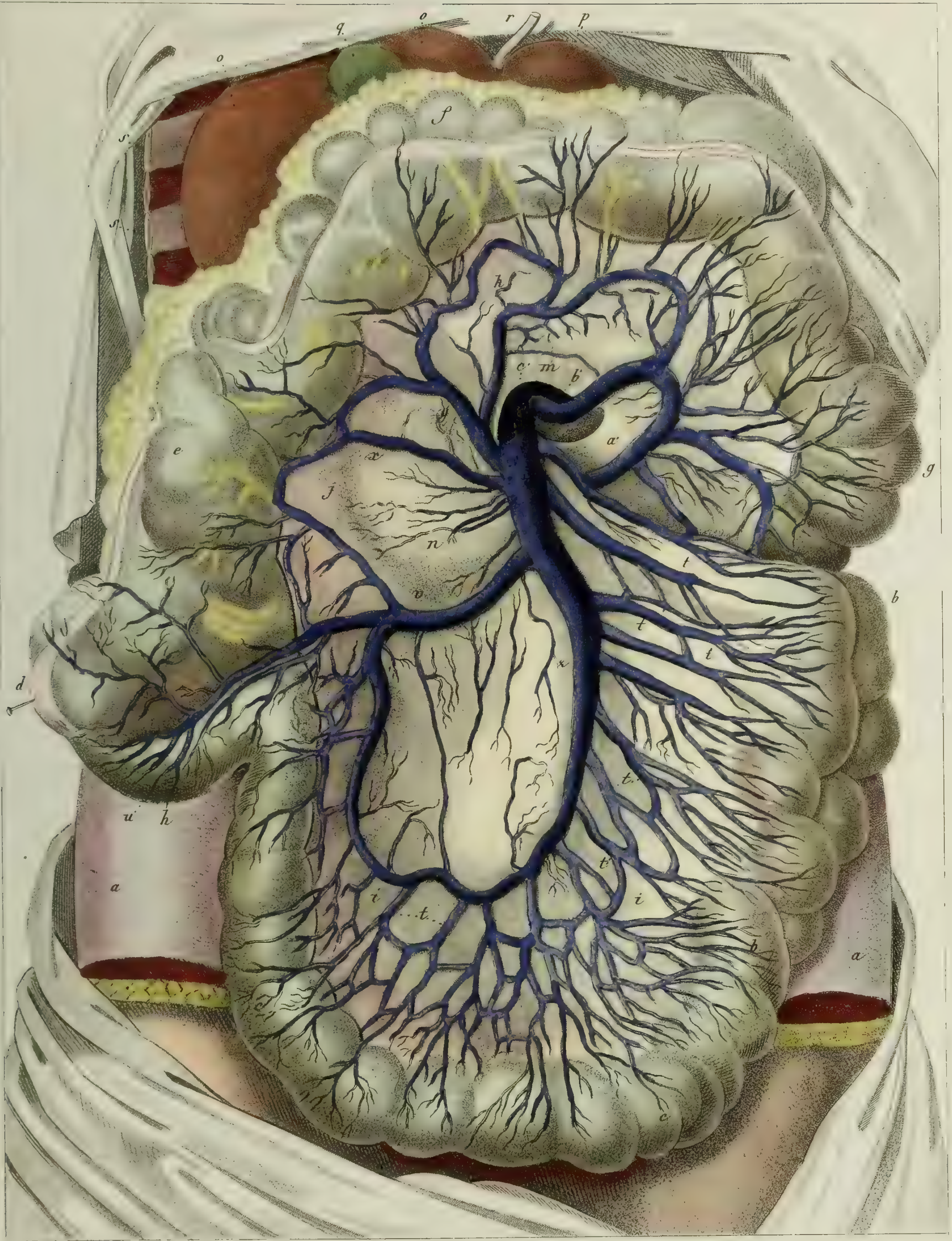

P. Dumenil Dirᵗ

VEINE MÉSENTÉRIQUE INFÉRIEURE.

P Dumenil Dir.t

VEINES GASTRO-ÉPIPLOÏQUES.

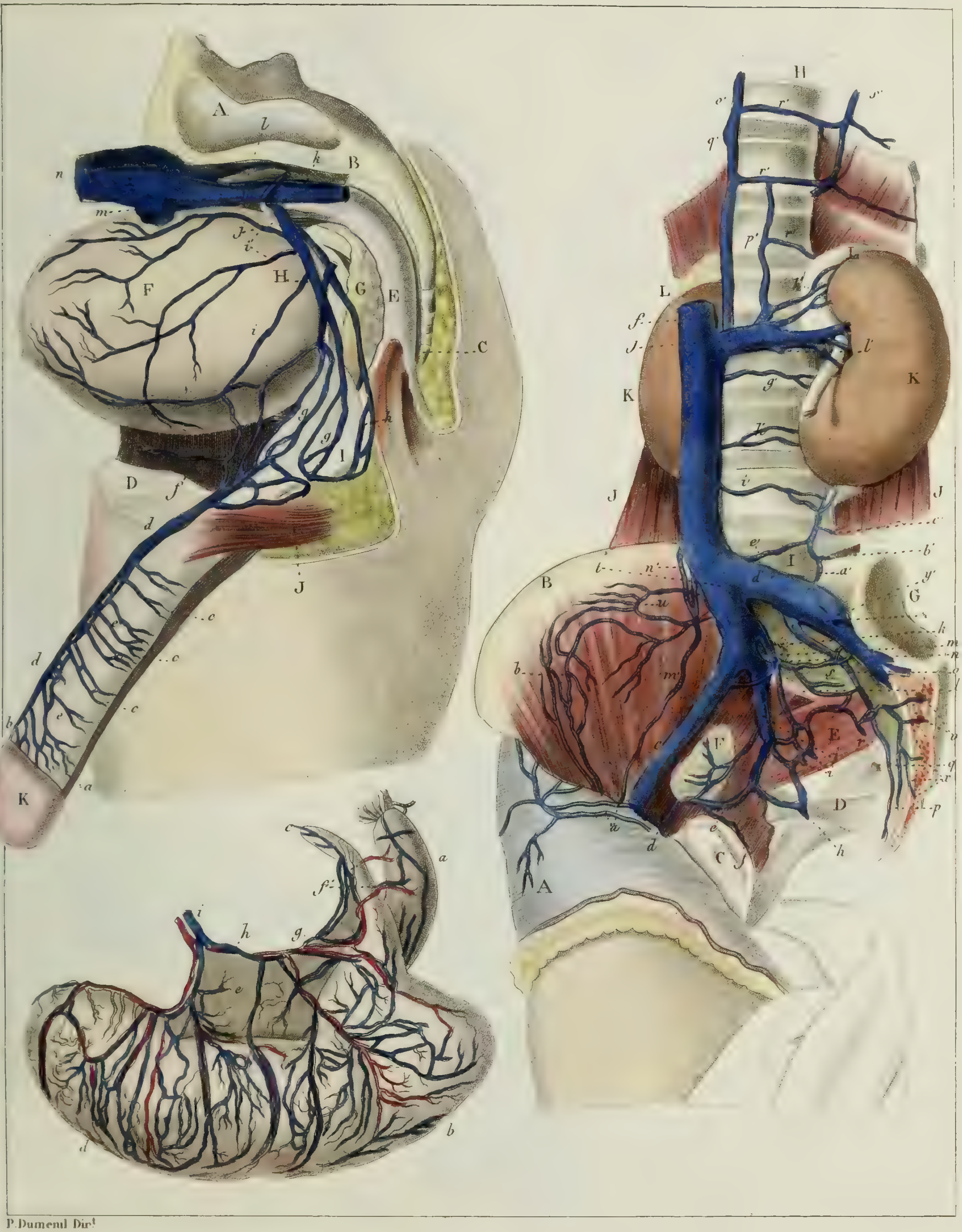

P. Dumenil Dir!

VEINE CAVE INFÉRIEURE.

Fig. 1.

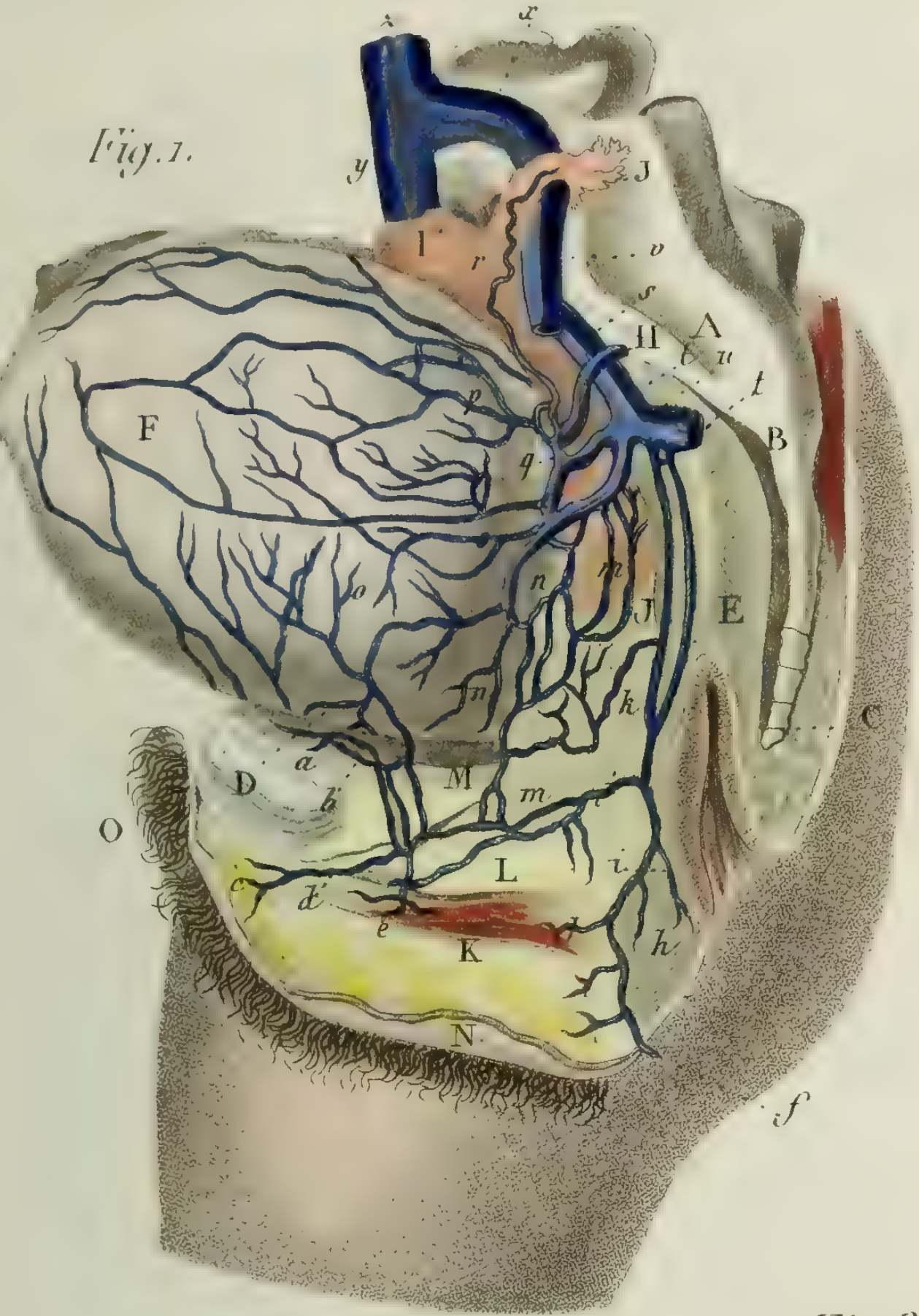

Fig. 2.

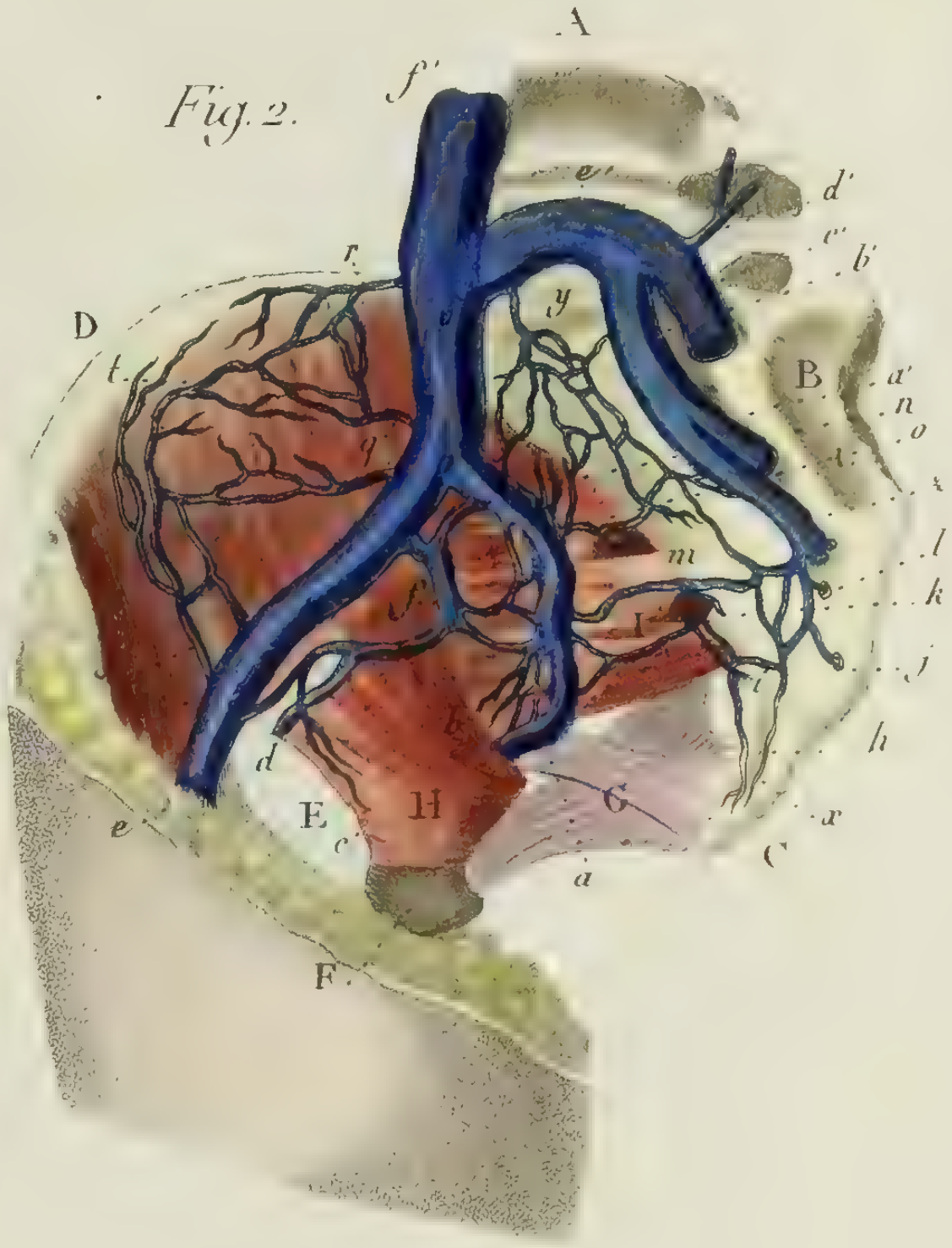

Fig. 3.

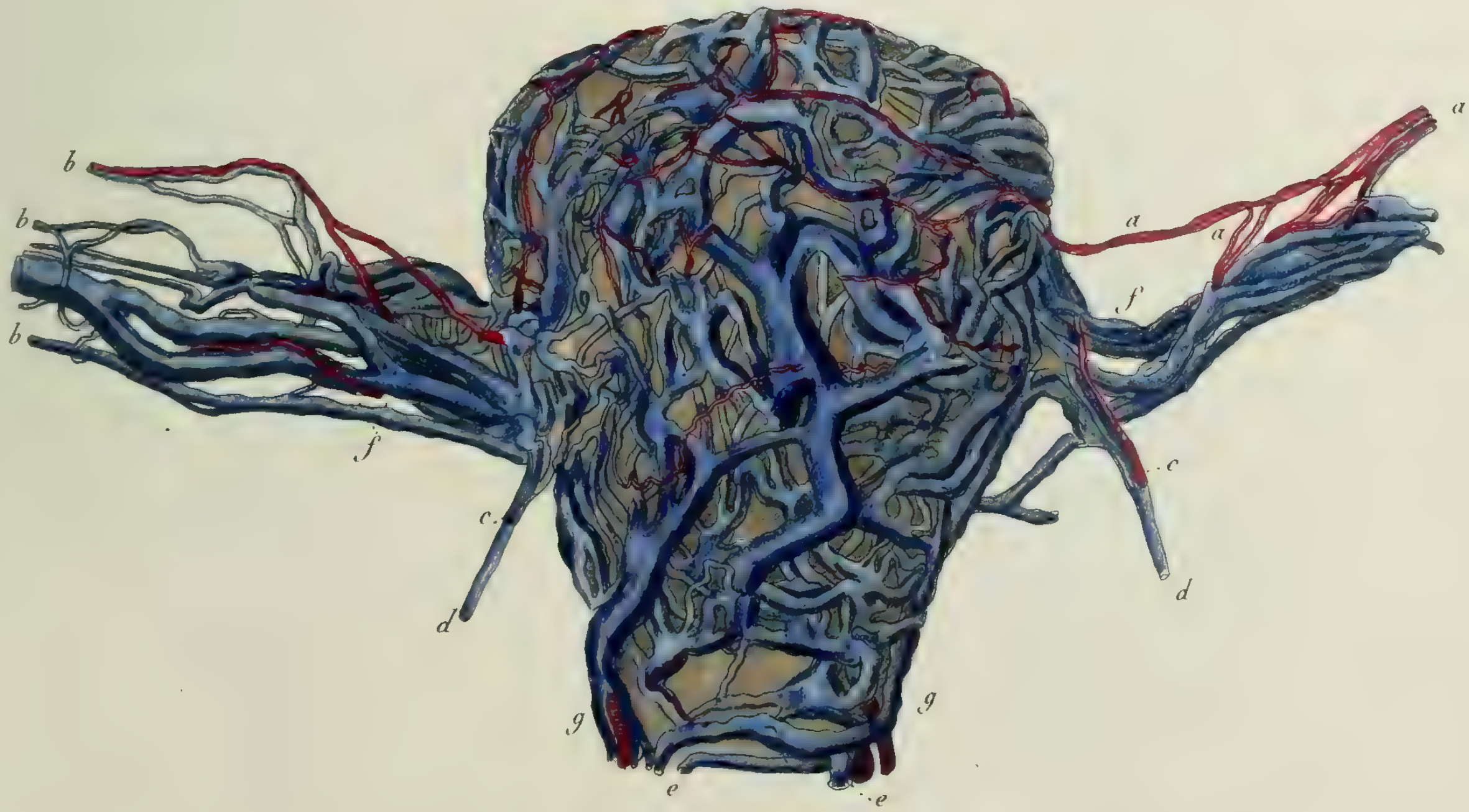

P Duménil Dir.t

VEINES DU BASSIN.

Fig. 2

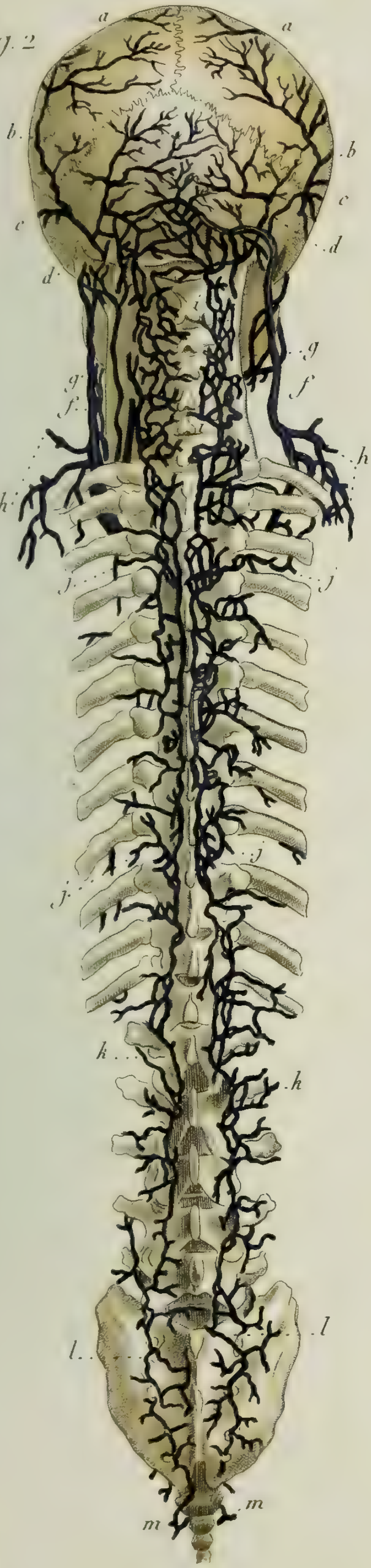

Fig. 1.

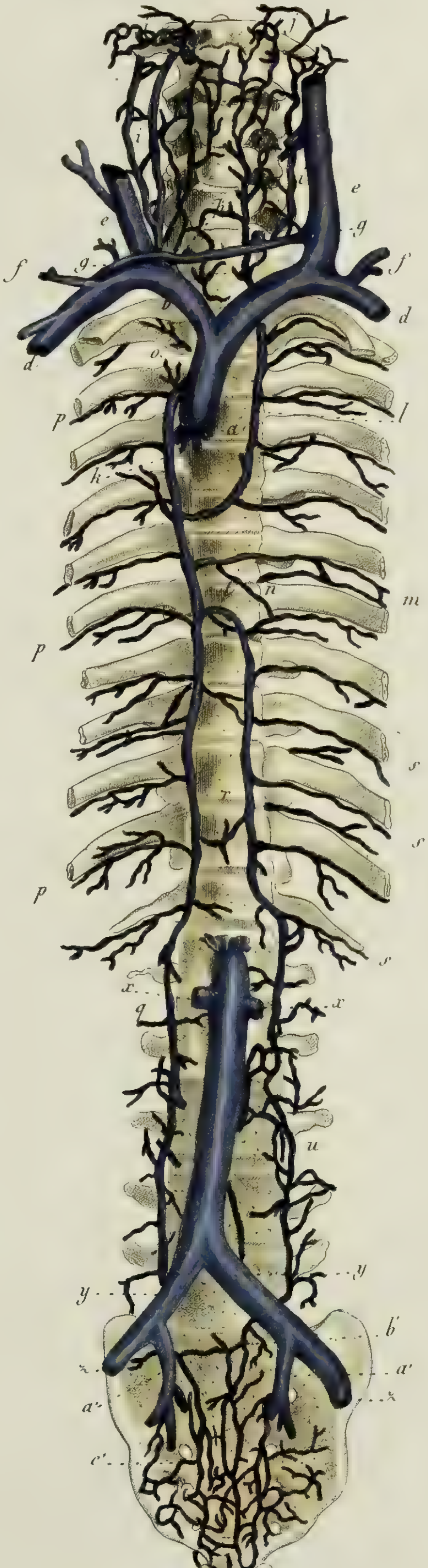

P Duménil Dir.t

VEINES DU RACHIS.

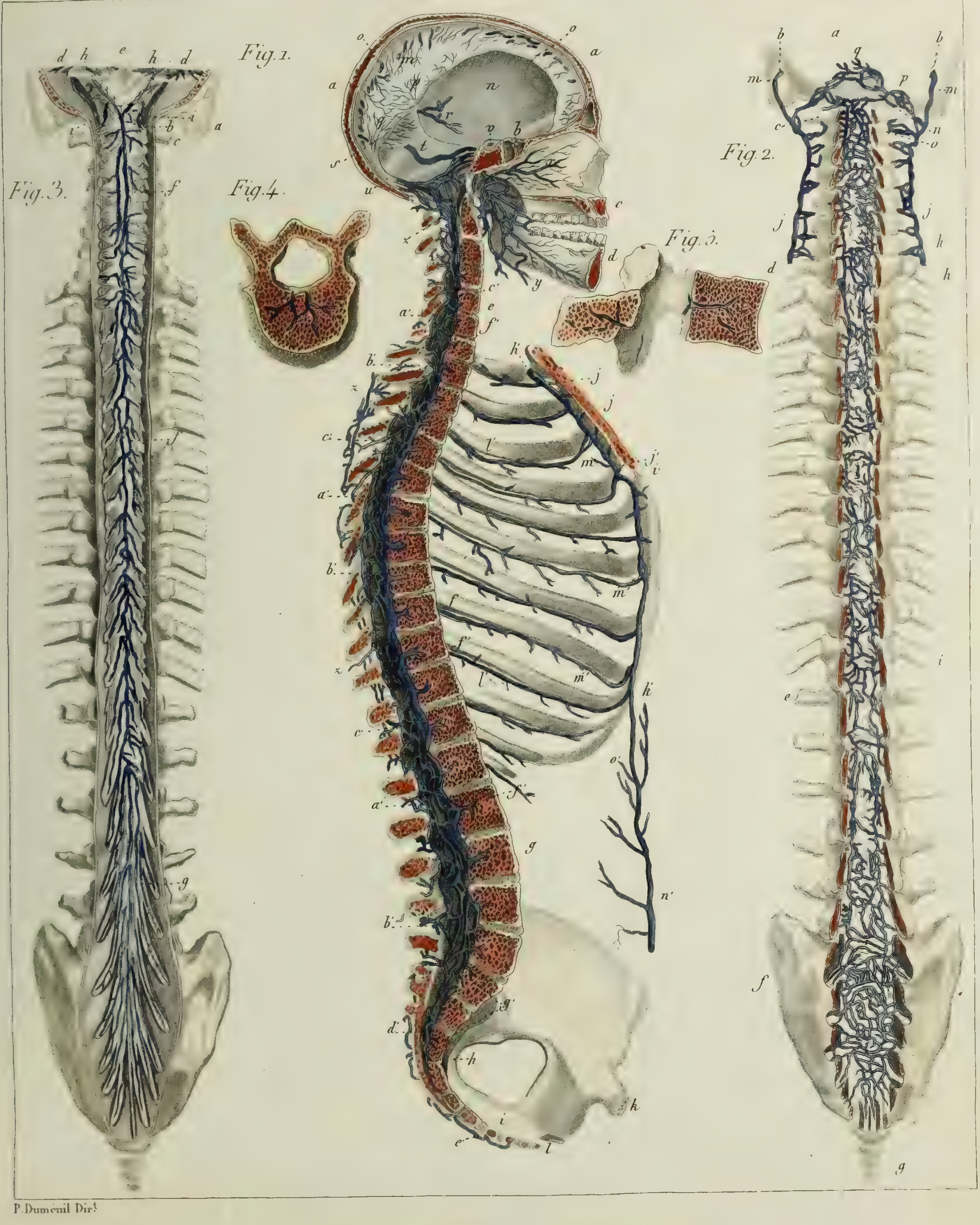

P. Duménil Dir.t

VEINES DU CRÂNE ET DU RACHIS.

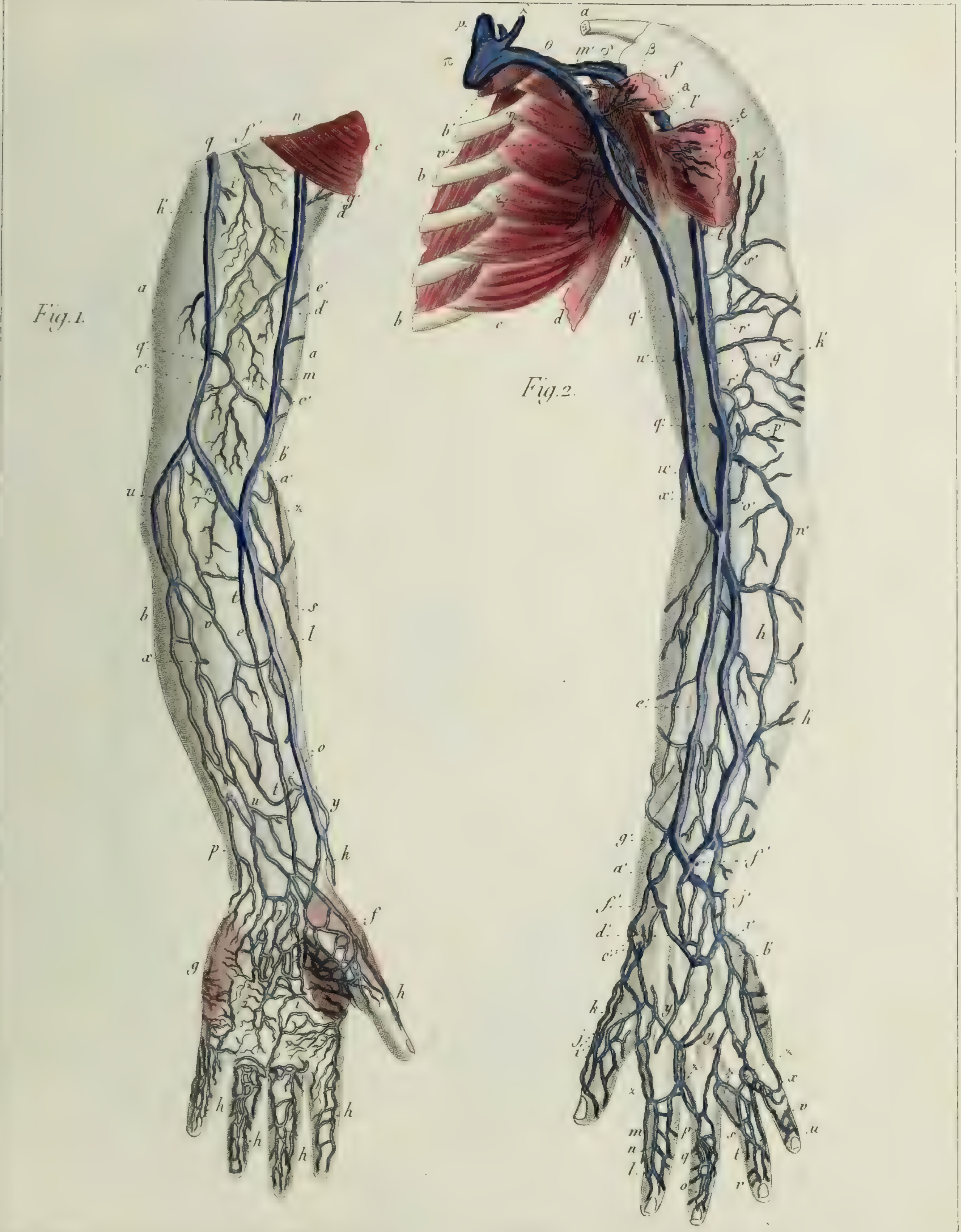

P Dumenil Dir.

VEINES SUPERFICIELLES DU BRAS.

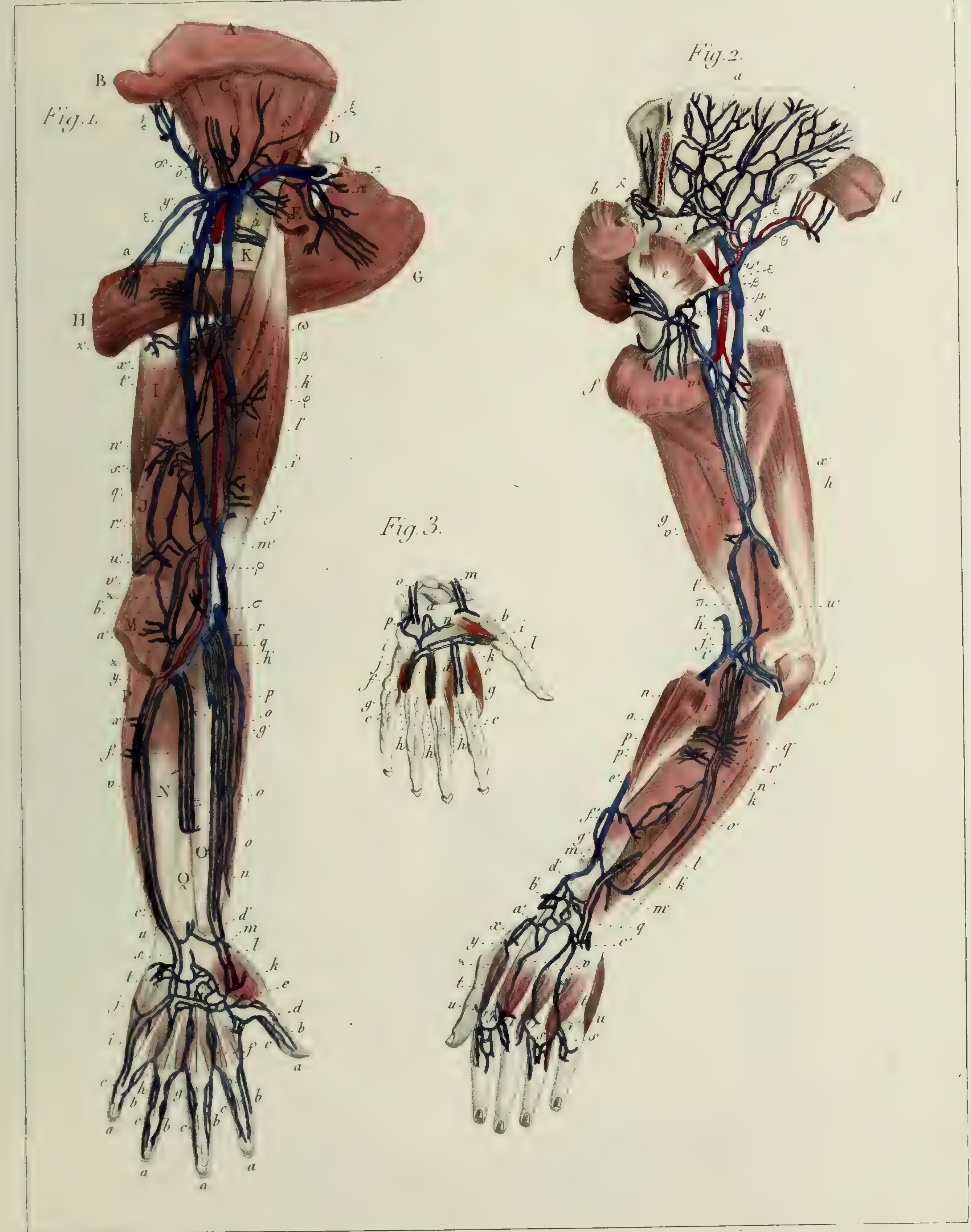

P Duménil Dir.t

VEINES PROFONDES DU MEMBRE SUPERIEUR.

P. Dumenil Dir.

VEINES SUPERFICIELLES DU MEMBRE INFÉRIEUR.

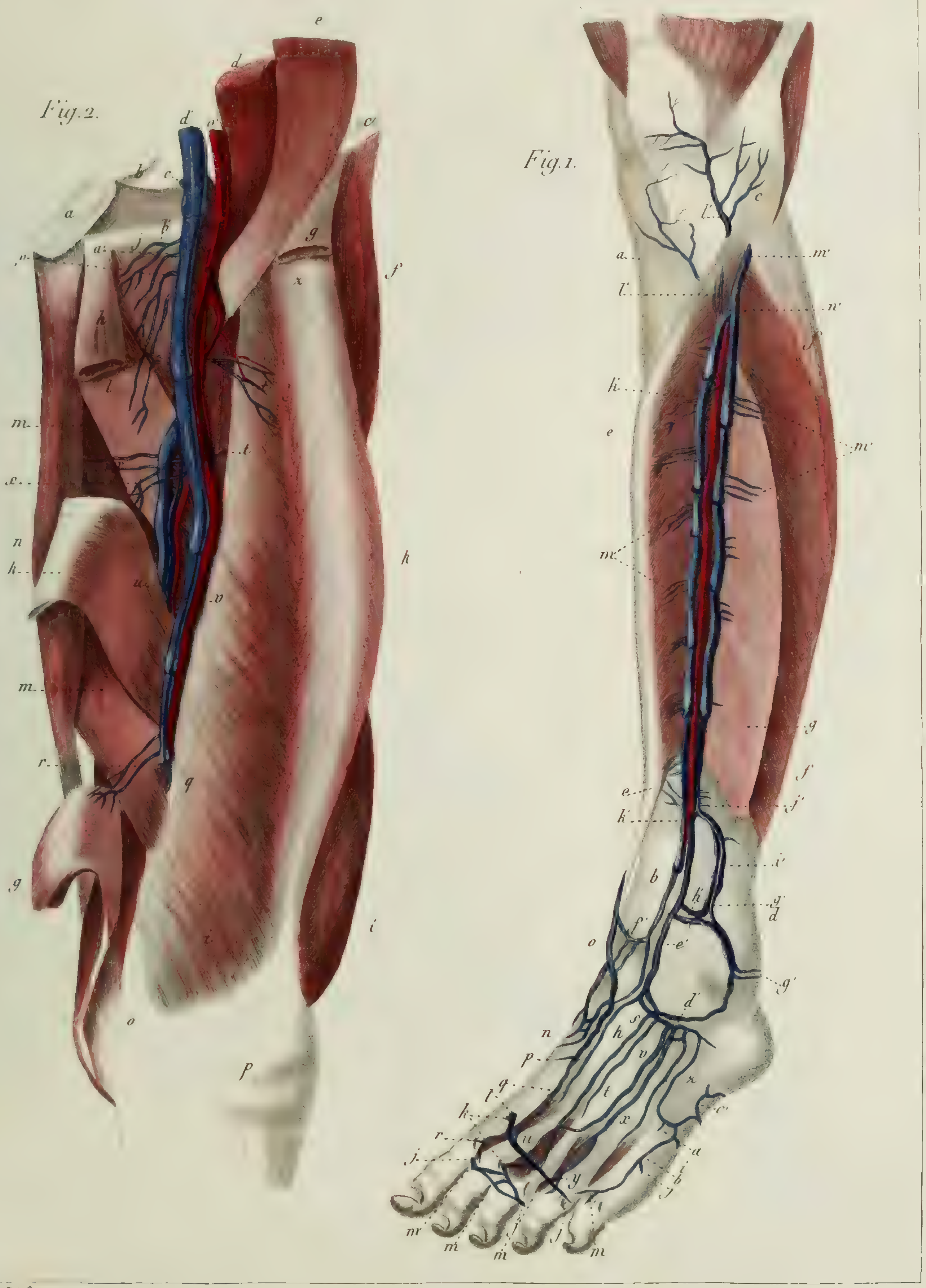

P. Duméril Dir.t

VEINES PROFONDES DU MEMBRE INFÉRIEURE

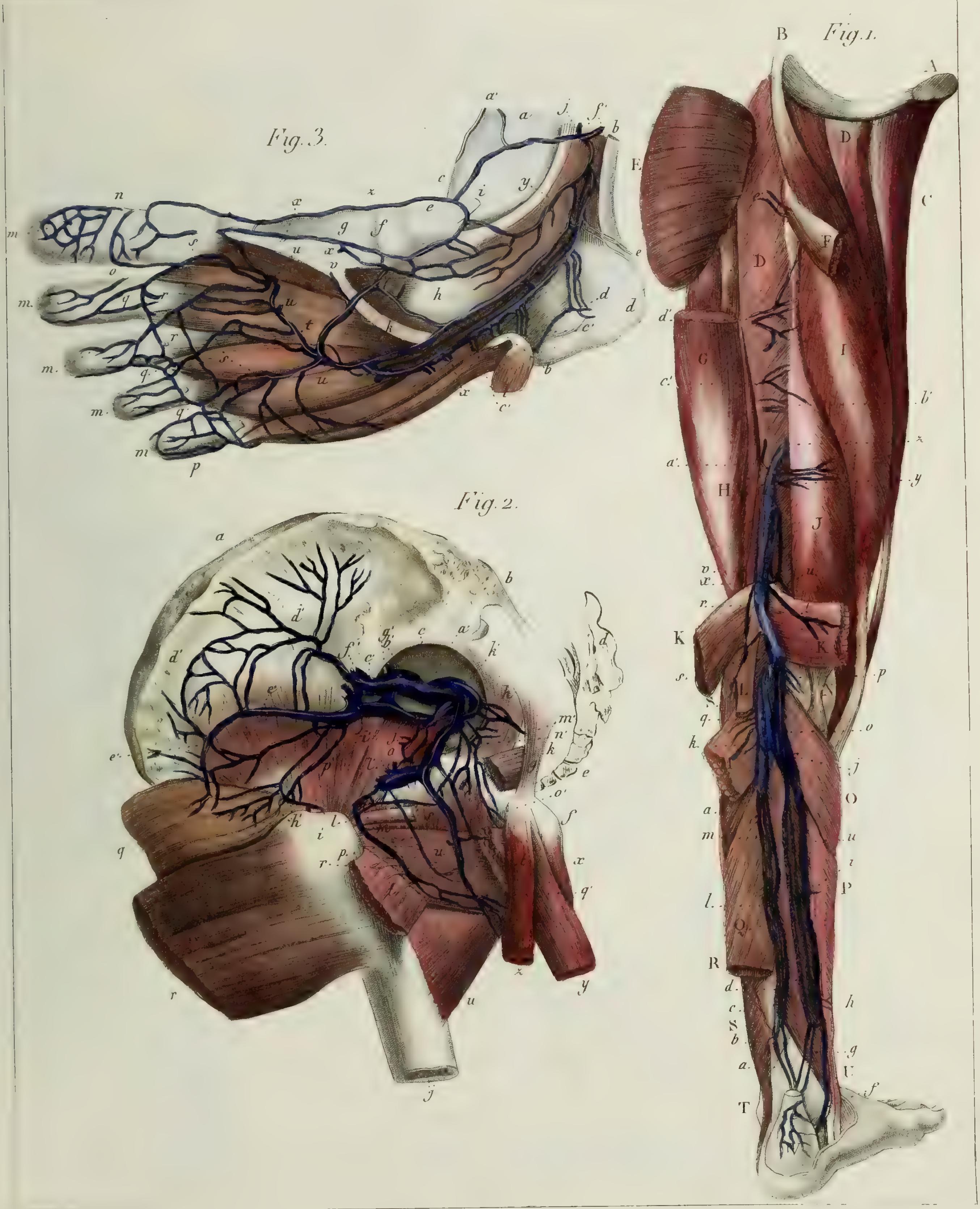

P. Dumenil Dir.t

VEINES PROFONDES DU MEMBRE INFÉRIEUR.

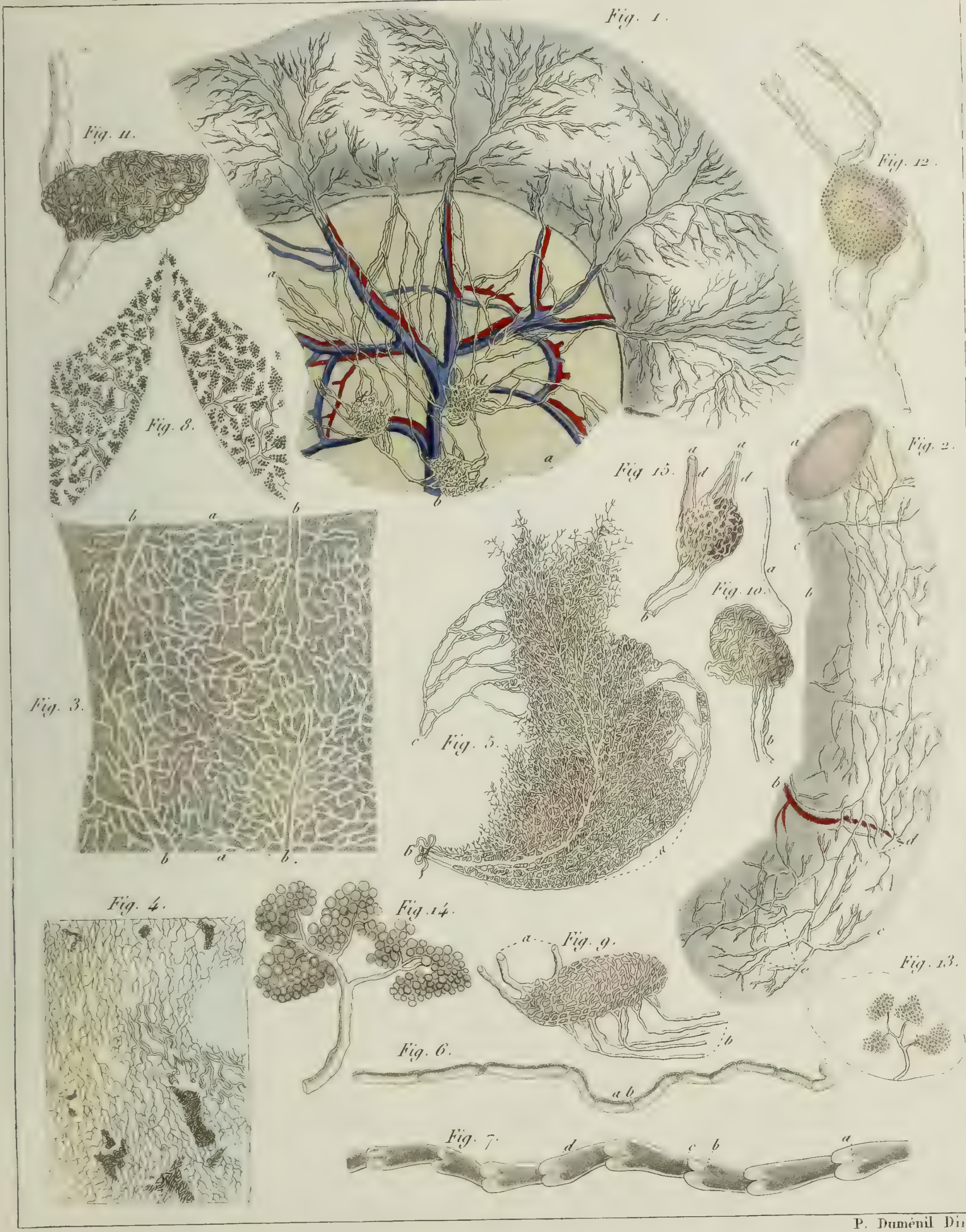

P. Duménil Dir!

VAISSEAUX ET GANGLIONS LYMPHATIQUES.

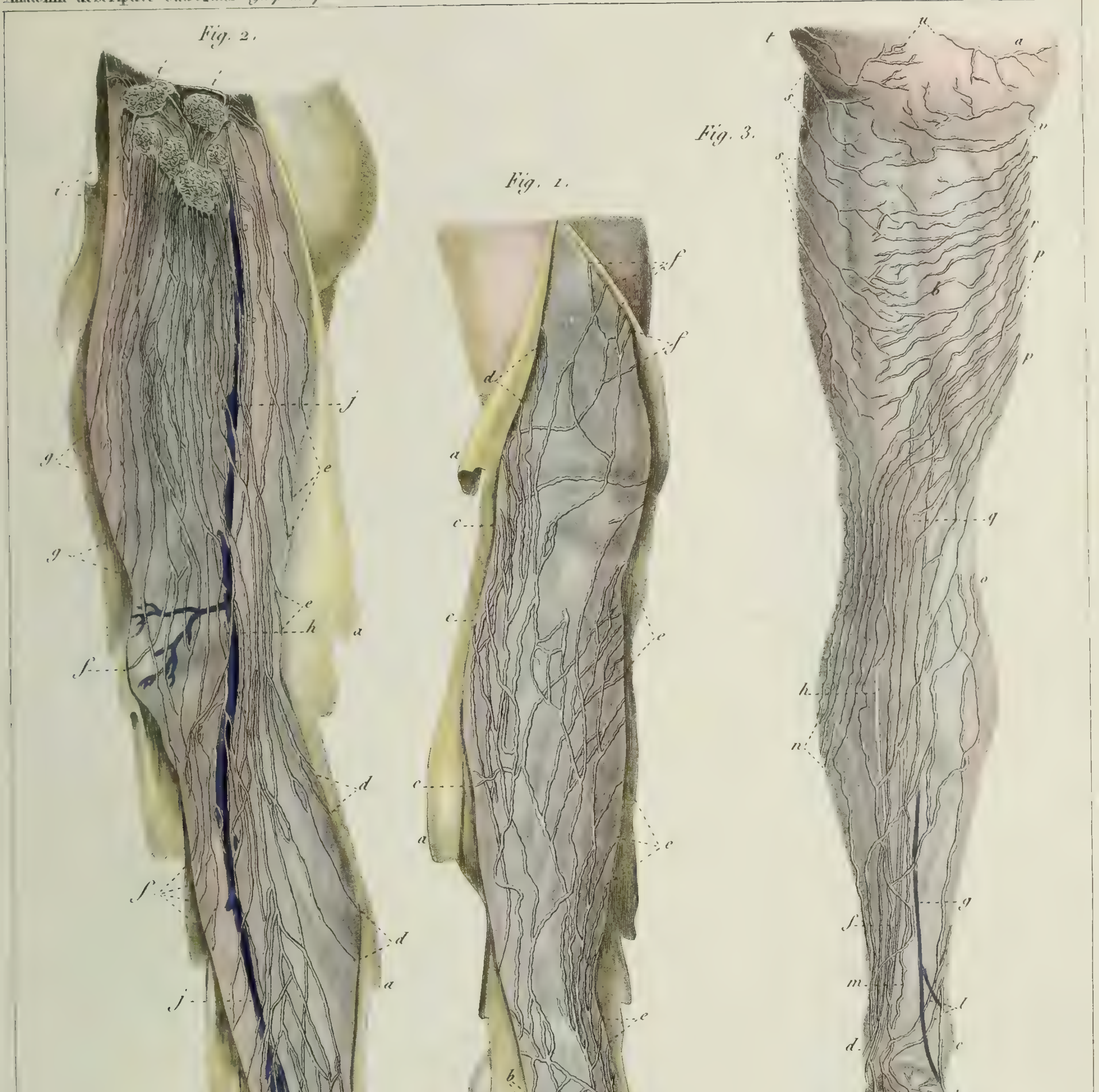

P. Duménil Dir.t

LYMPHATIQUES DES MEMBRES ABDOMINAUX.

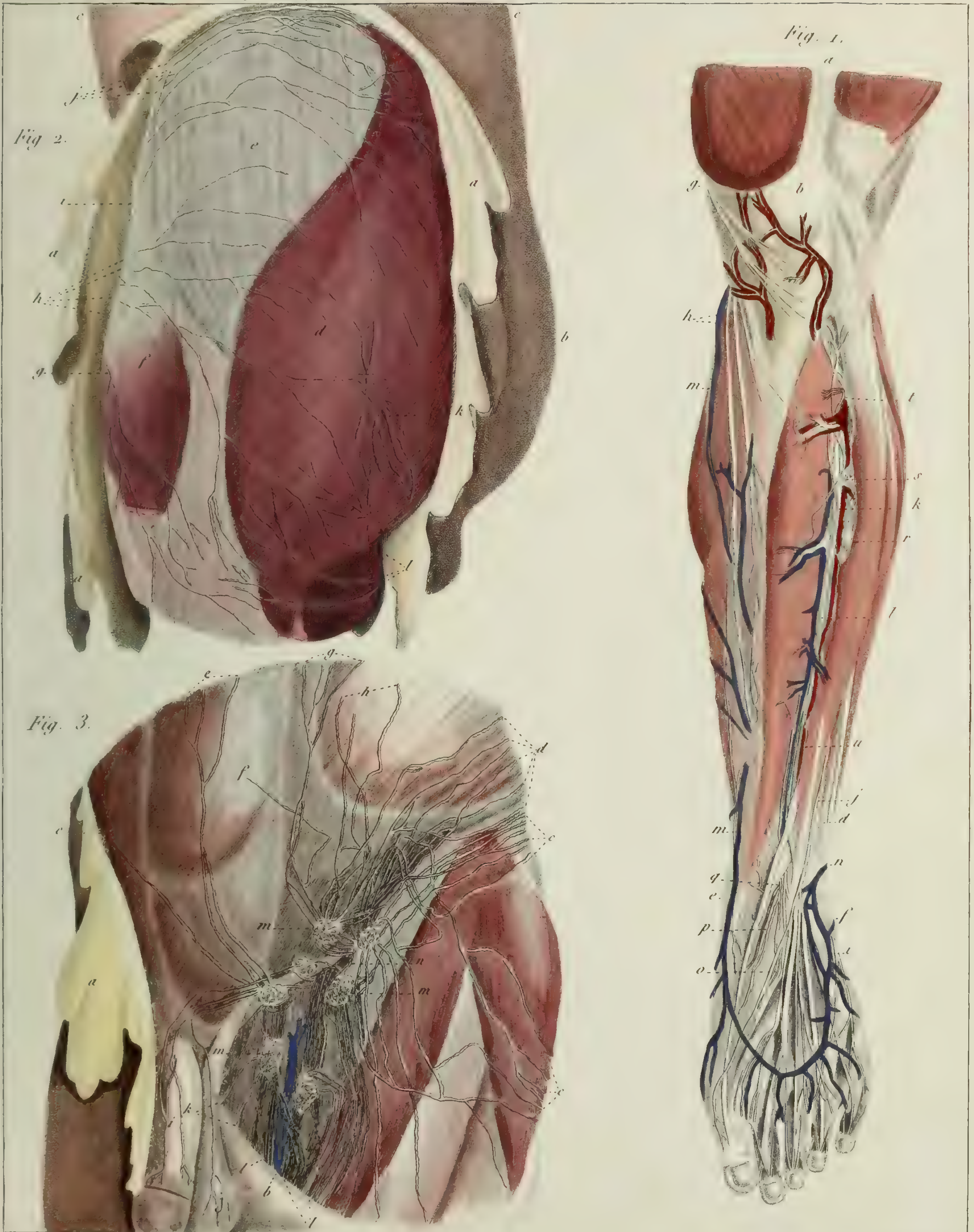

P. Duménil Dir.t

LYMPHATIQUES DES MEMBRES ABDOMINAUX.

Fig. 1.

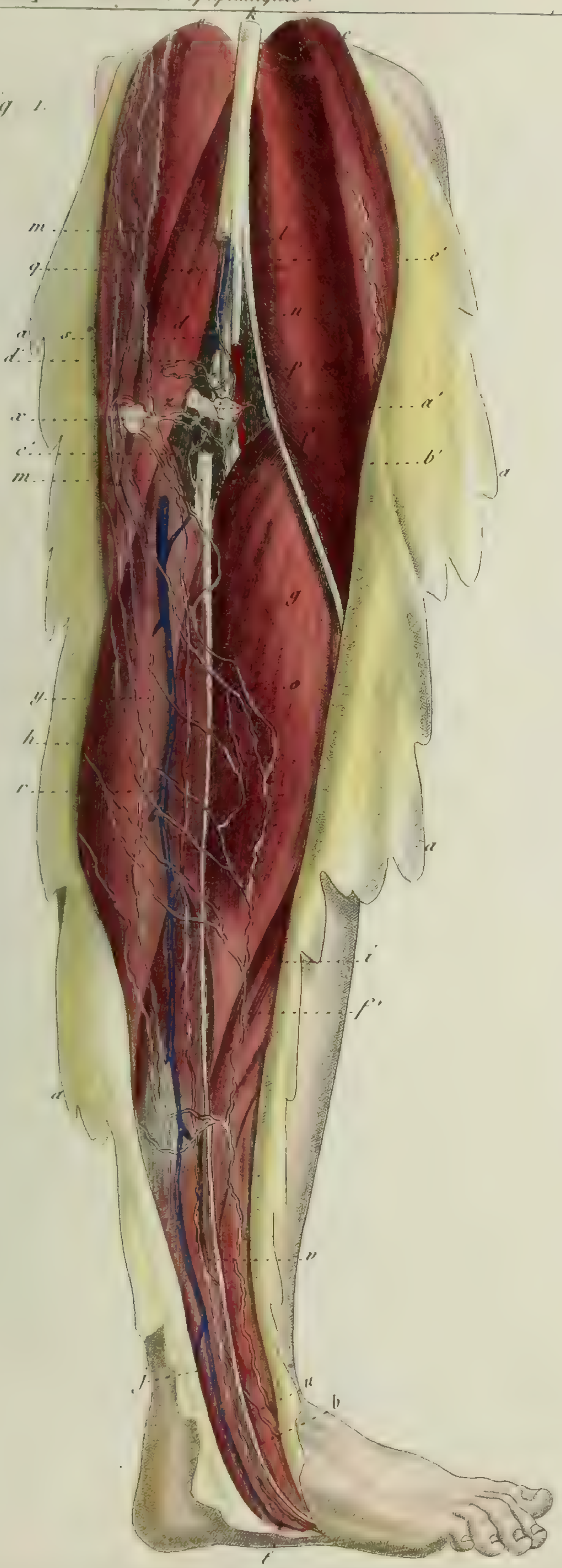

Fig. 2.

P. Duménil Dir.

LYMPHATIQUES DES MEMBRES ABDOMINAUX.

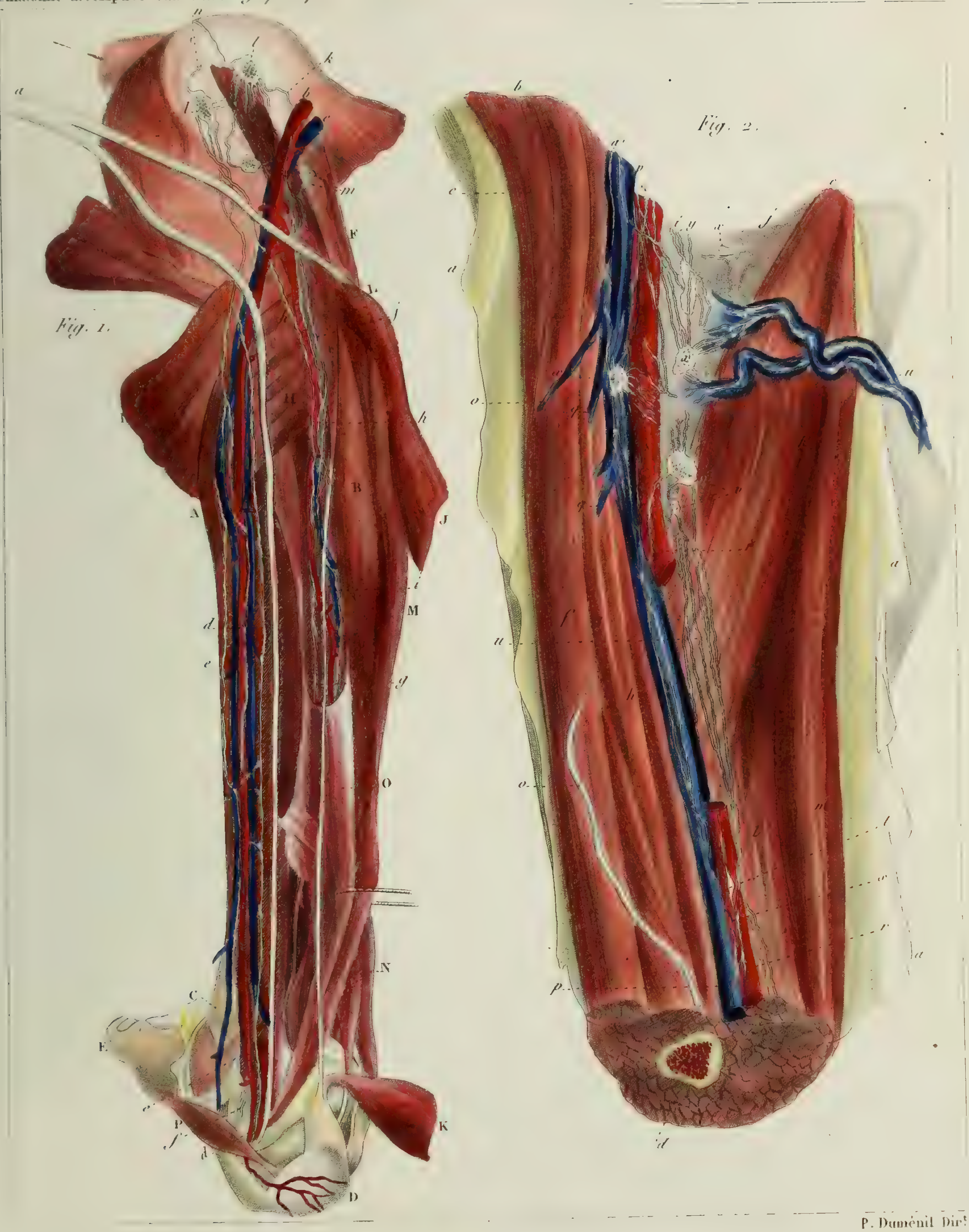

P. Duménil Dir!

LYMPHATIQUES DES MEMBRES ABDOMINAUX.

Fig. 1.

Fig. 2.

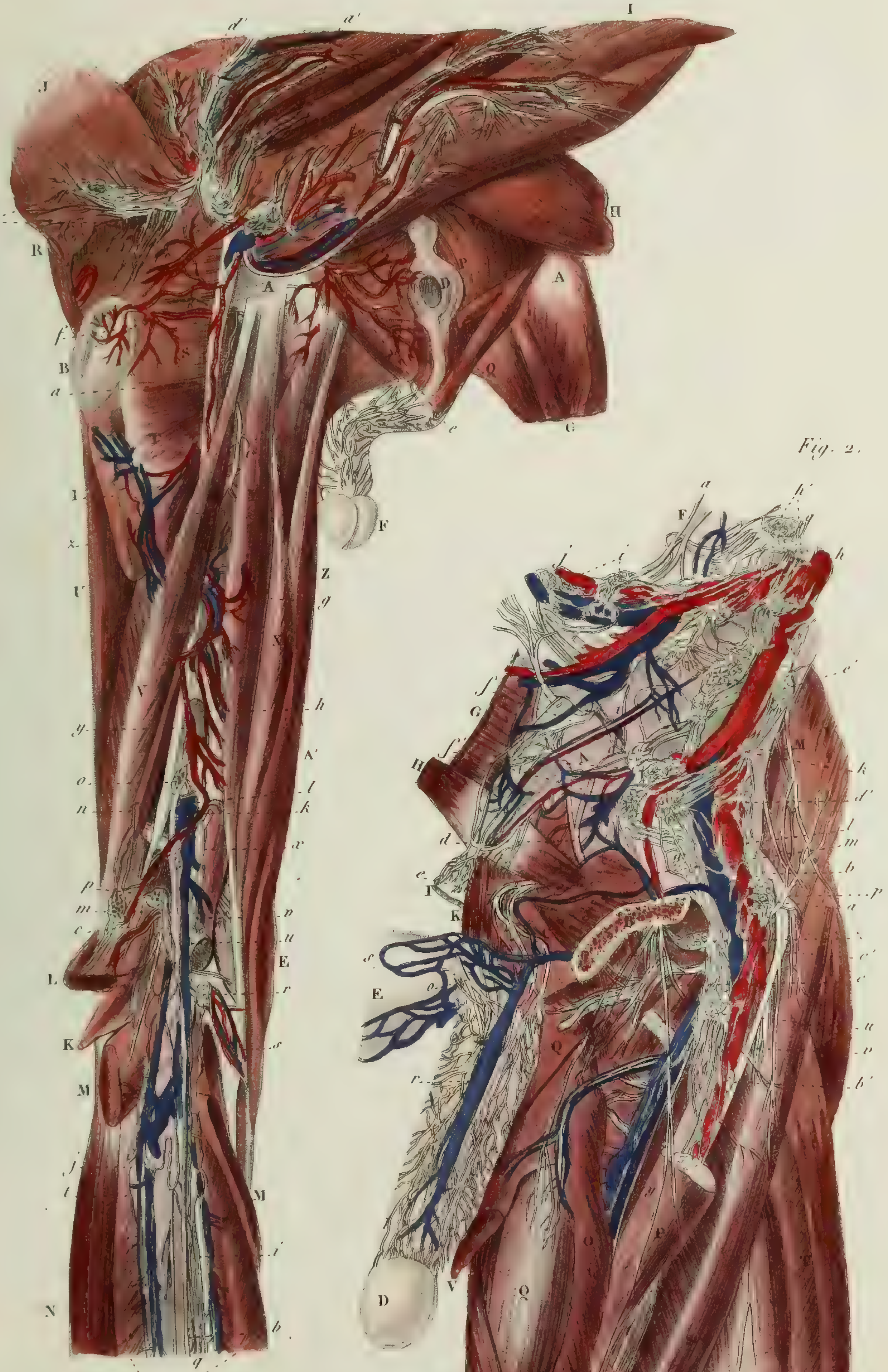

P. Duménil Dir^t

LYMPHATIQUES DU BASSIN ET DE LA CUISSE.

Fig. 1.

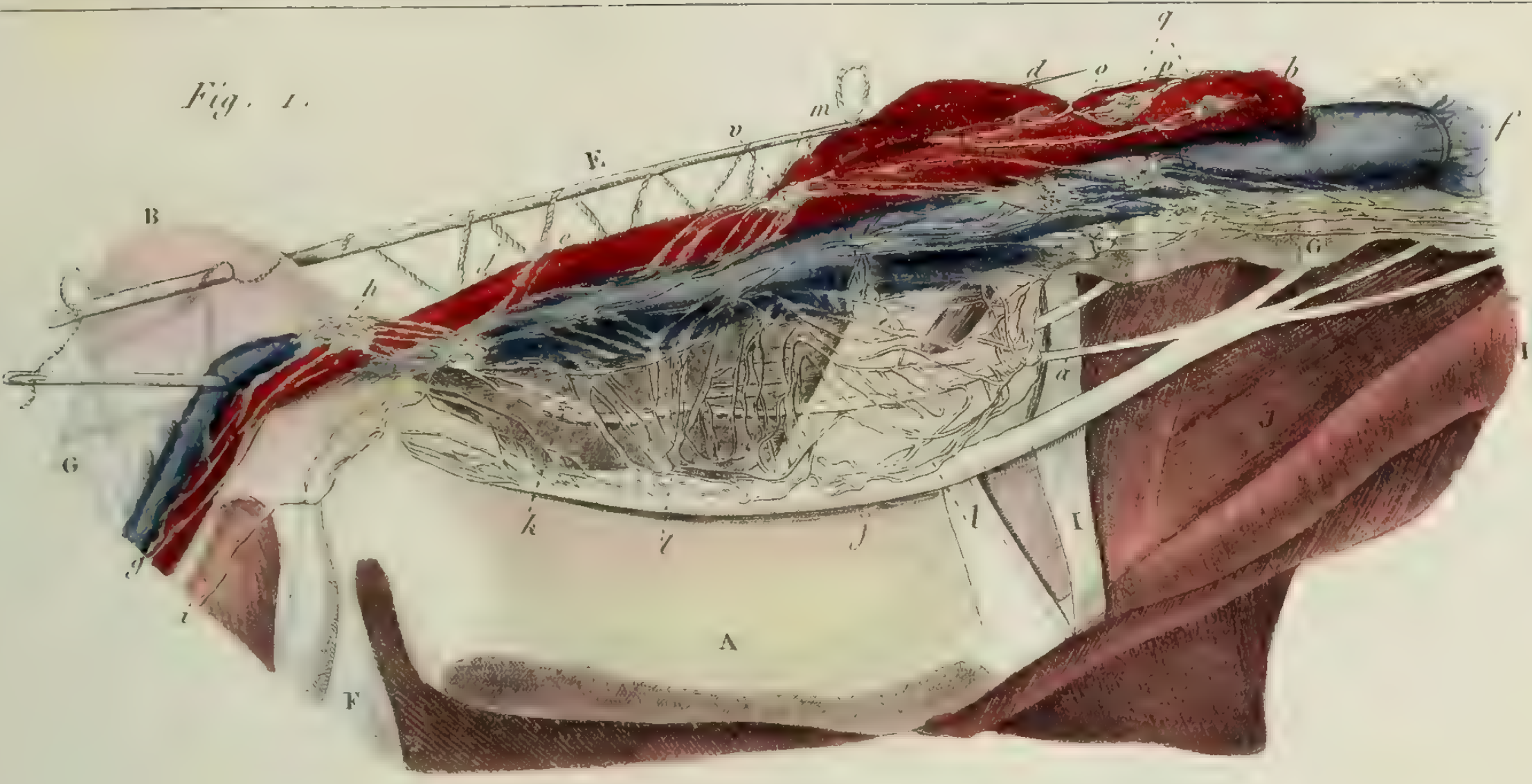

Fig. 2.

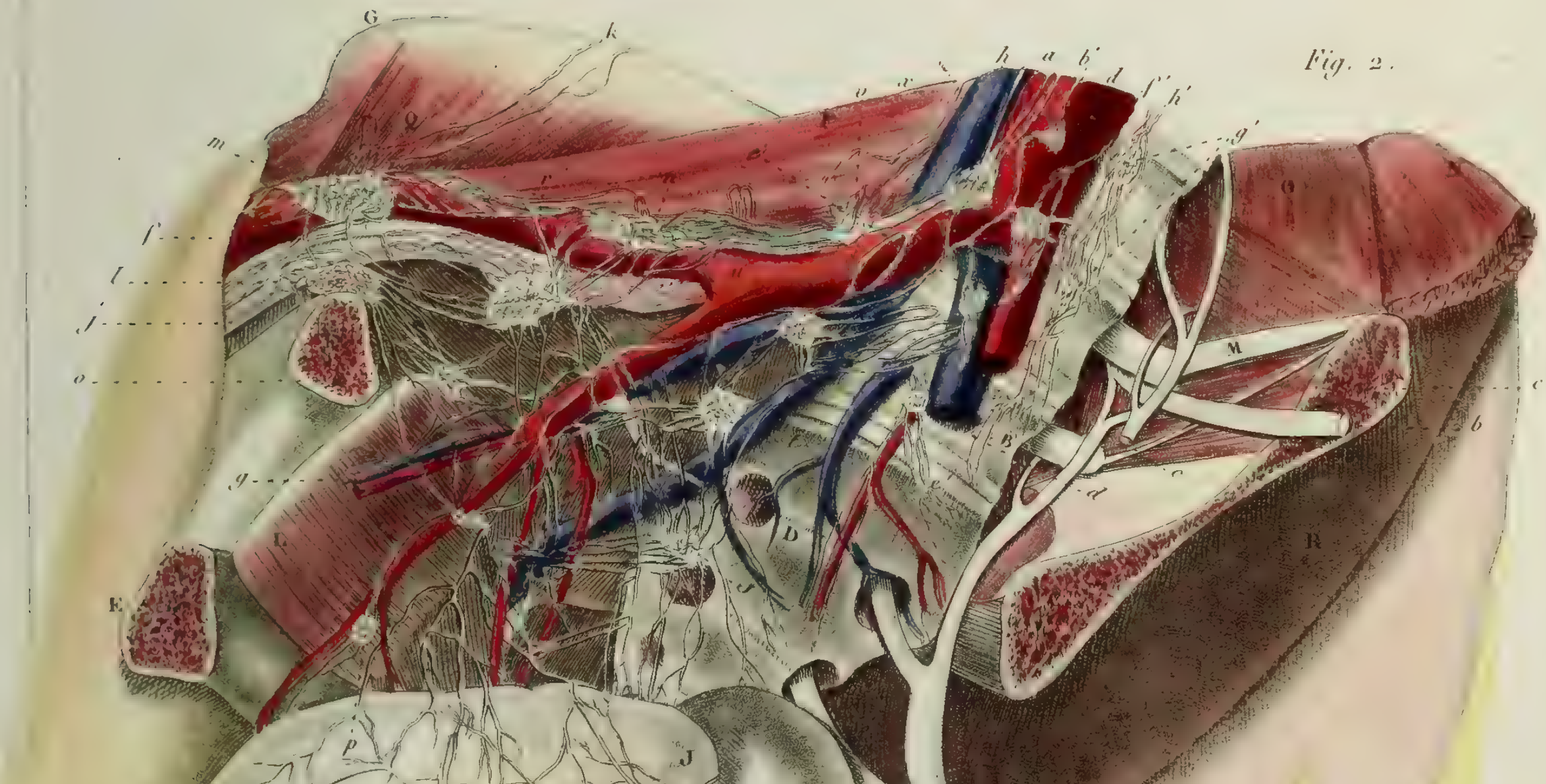

P. Duménil Dir!

LYMPHATIQUES DU BASSIN.

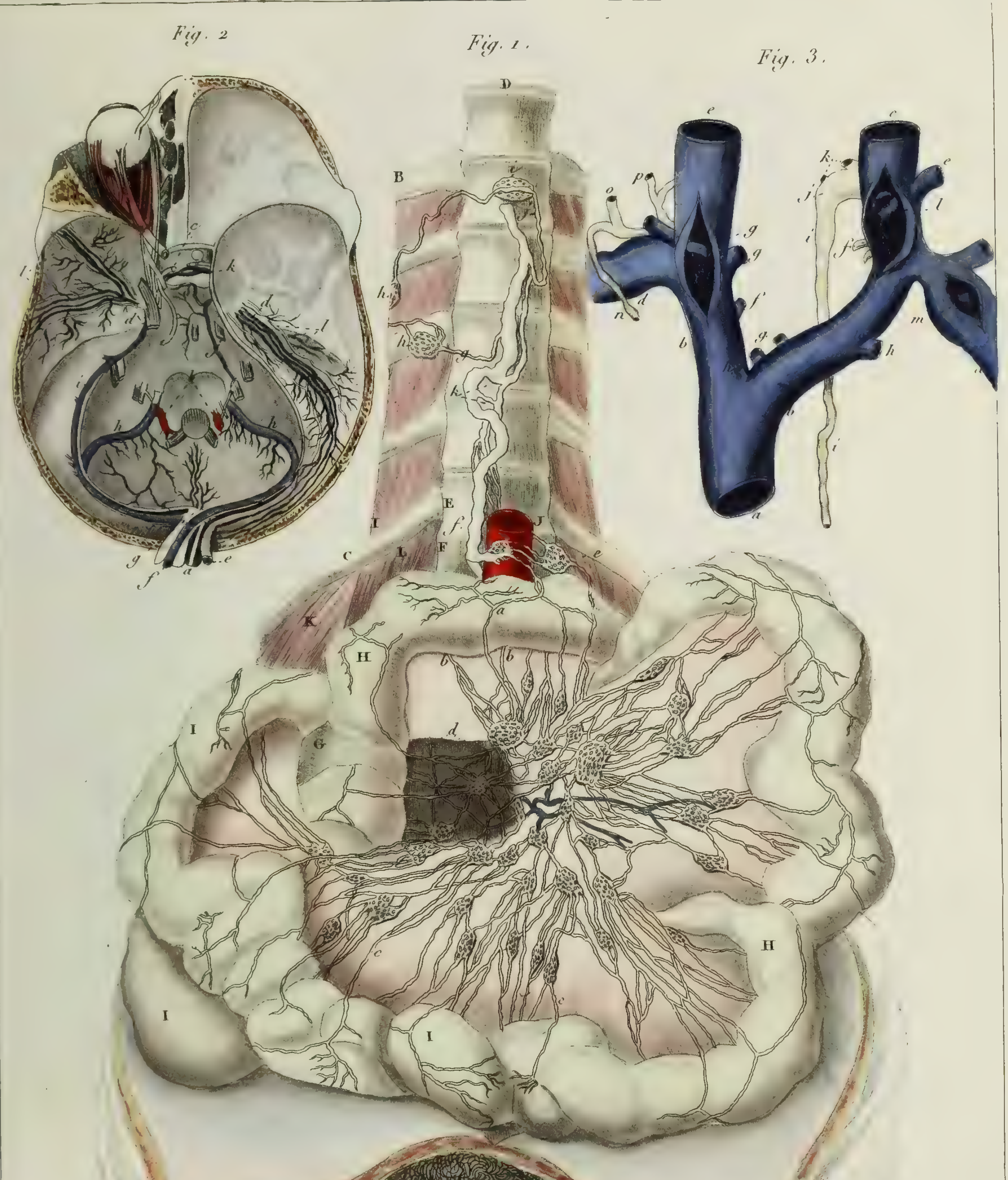

P. Duménil Dir.

CANAL THORACHIQUE.

P. Duménil Dir.

LYMPHATIQUES DE L'ABDOMEN.

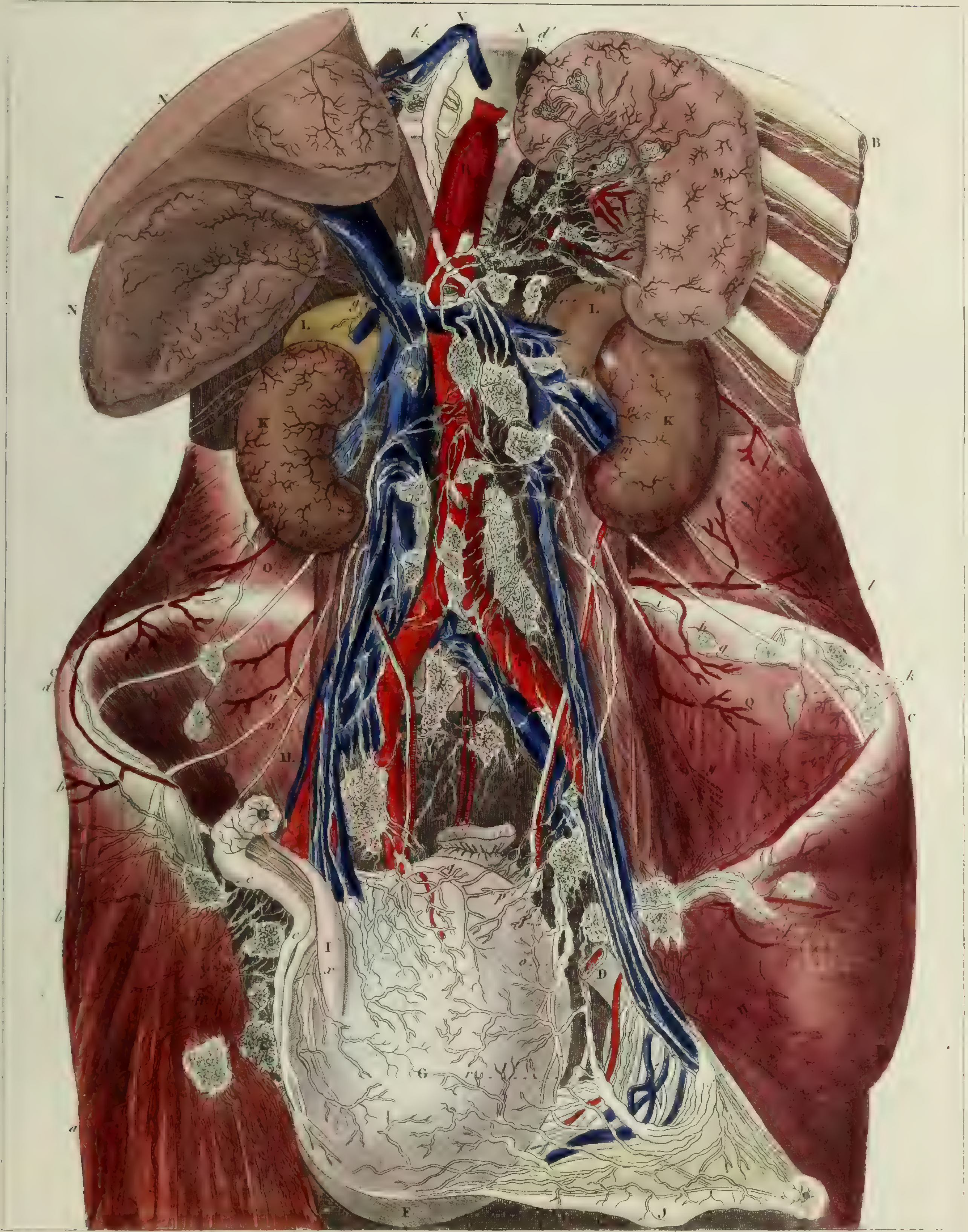

P. Duménil Dir.t

LYMPHATIQUES DE L'ABDOMEN.

P. Duménil Dir.

LYMPHATIQUES DE L'ABDOMEN.

P. Duménil Dir.t

LYMPHATIQUES DU FOIE.

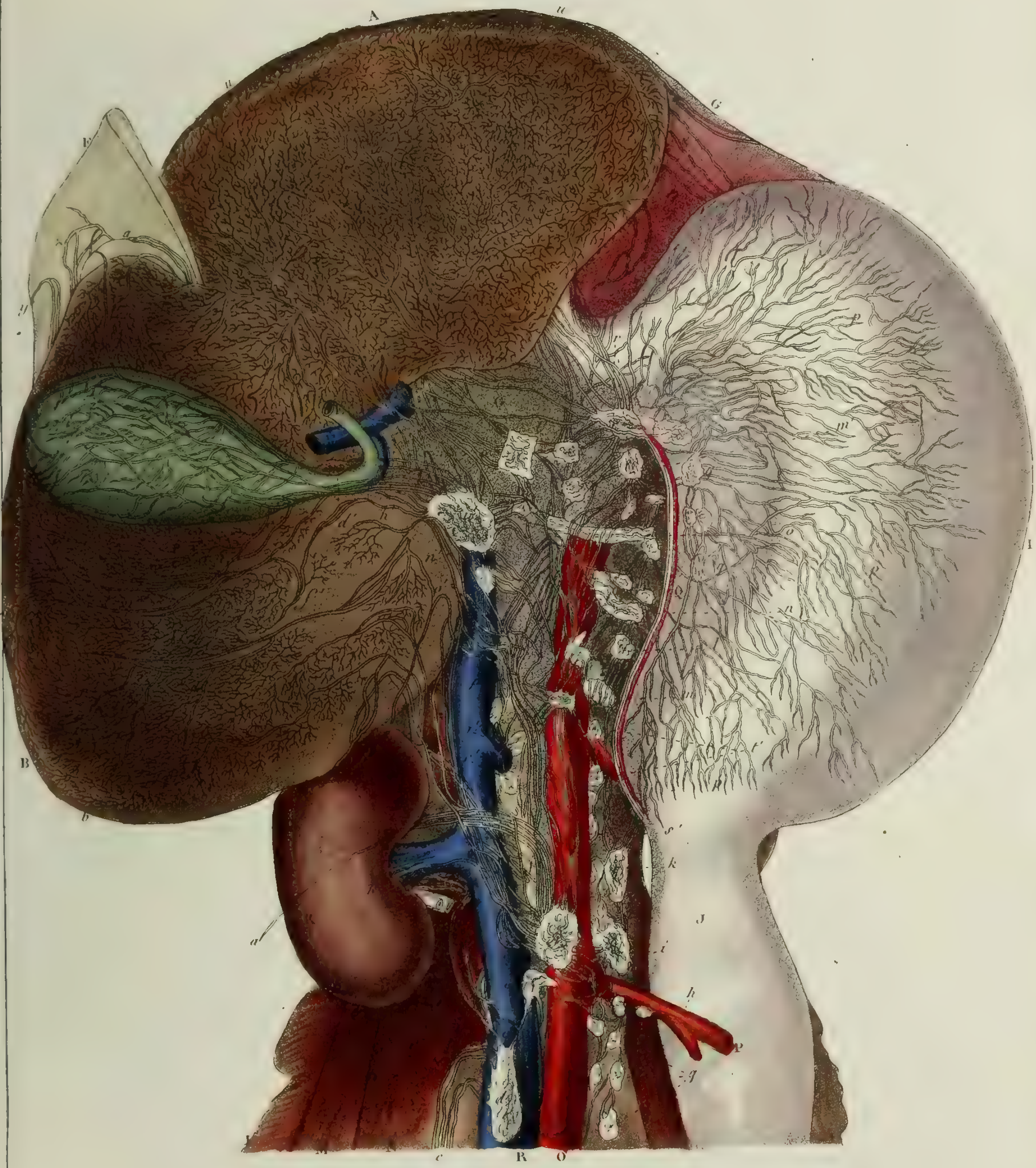

P. Duménil Dir.t

LYMPHATIQUES DU FOIE ET DE L'ESTOMAC.

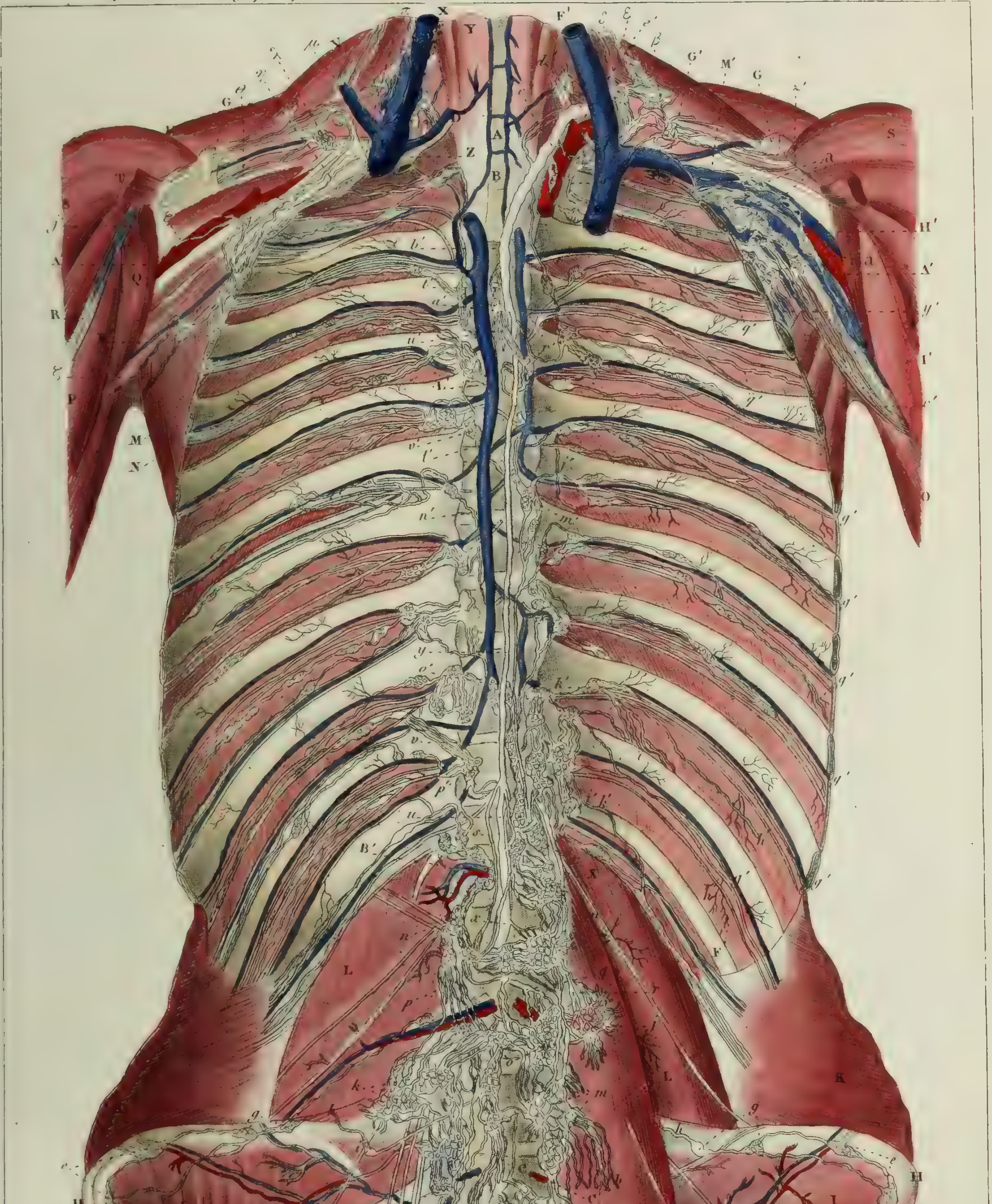

P. Duménil Dir.

CANAL THORACHIQUE

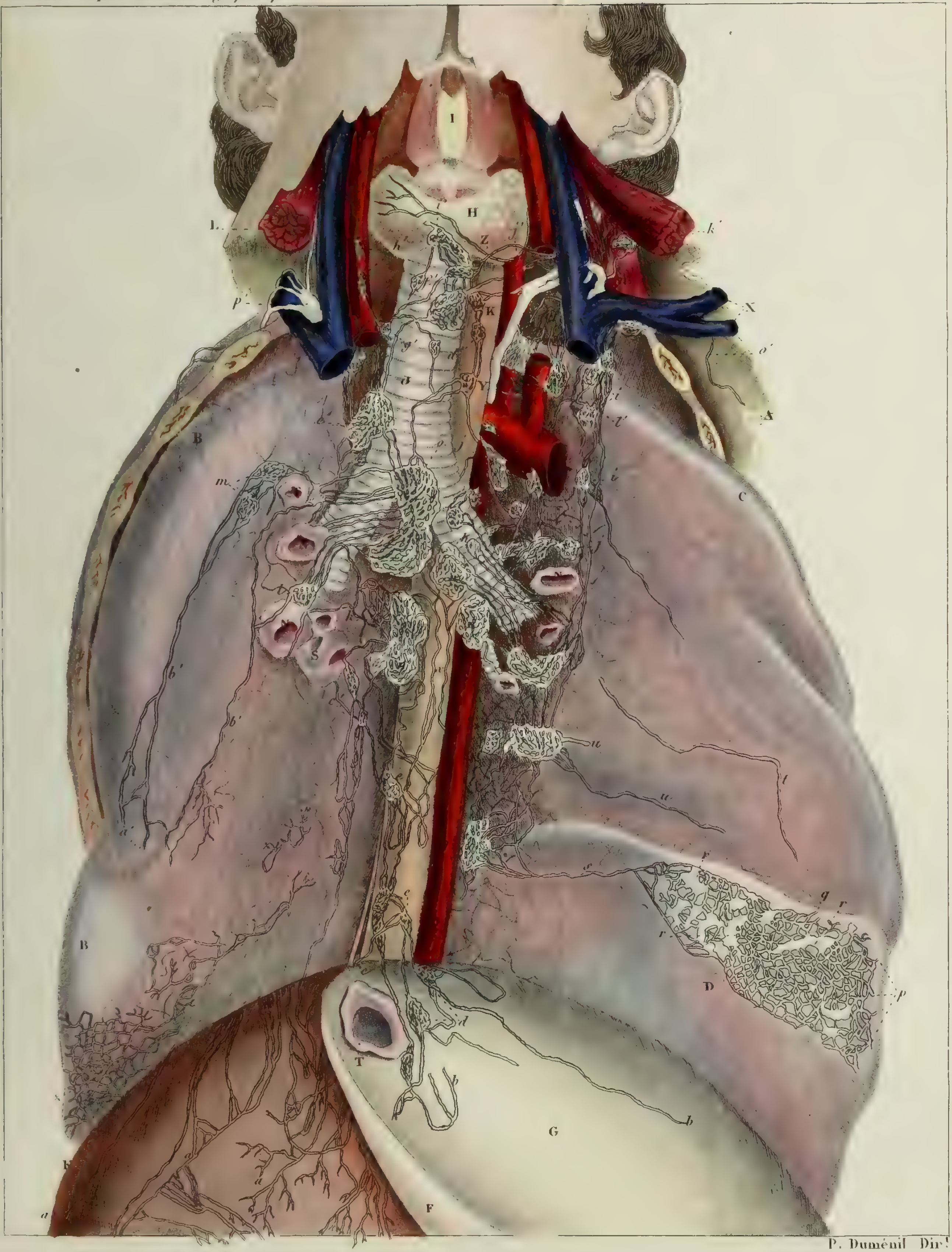

P. Duménil Dir!

LYMPHATIQUES DES POUMONS.

Fig. 1.

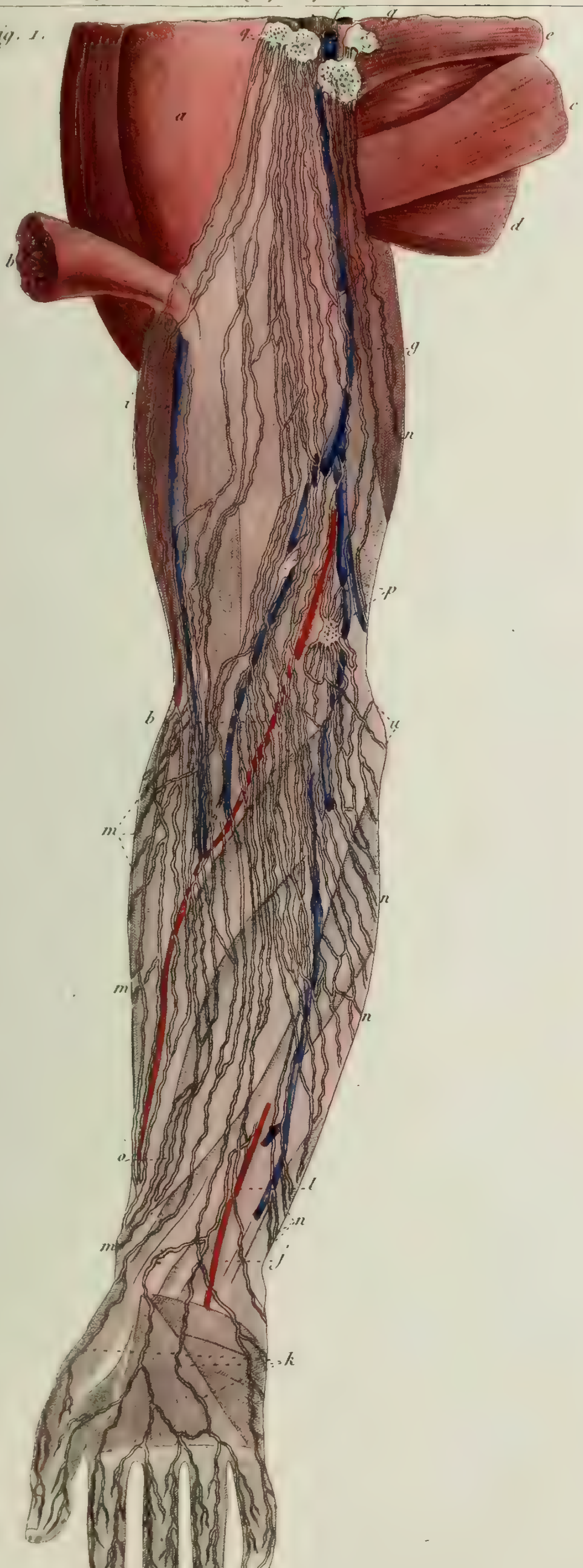

Fig. 2.

P. Duménil Dir.

LYMPHATIQUES SUPERFICIELS DU BRAS.

P. Duménil Dir.

LYMPHATIQUES SUPERFICIELS DE LA TÊTE ET DU THORAX.

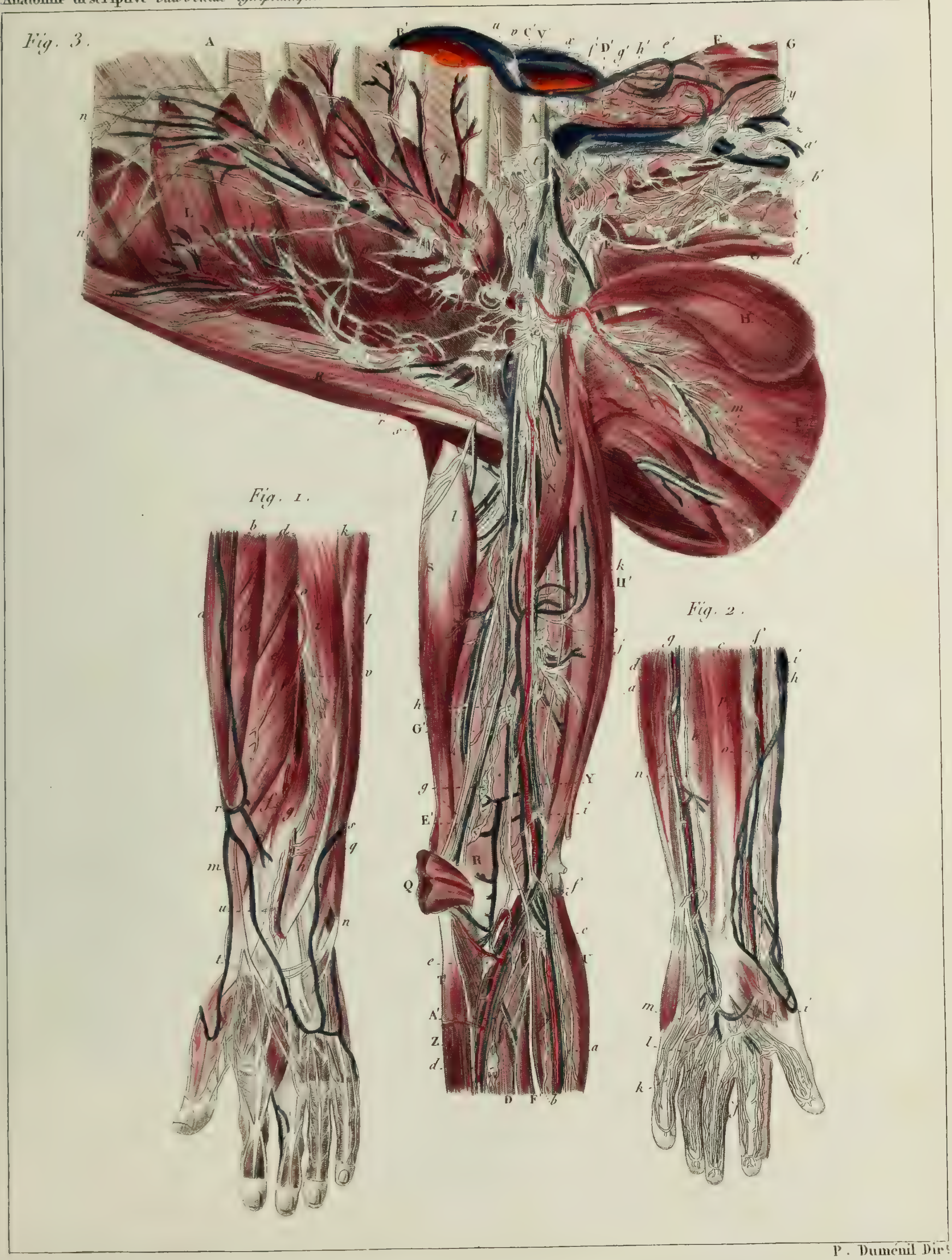

P. Duménil Dir.

LYMPHATIQUES PROFONDS DES MEMBRES SUPERIEURS.

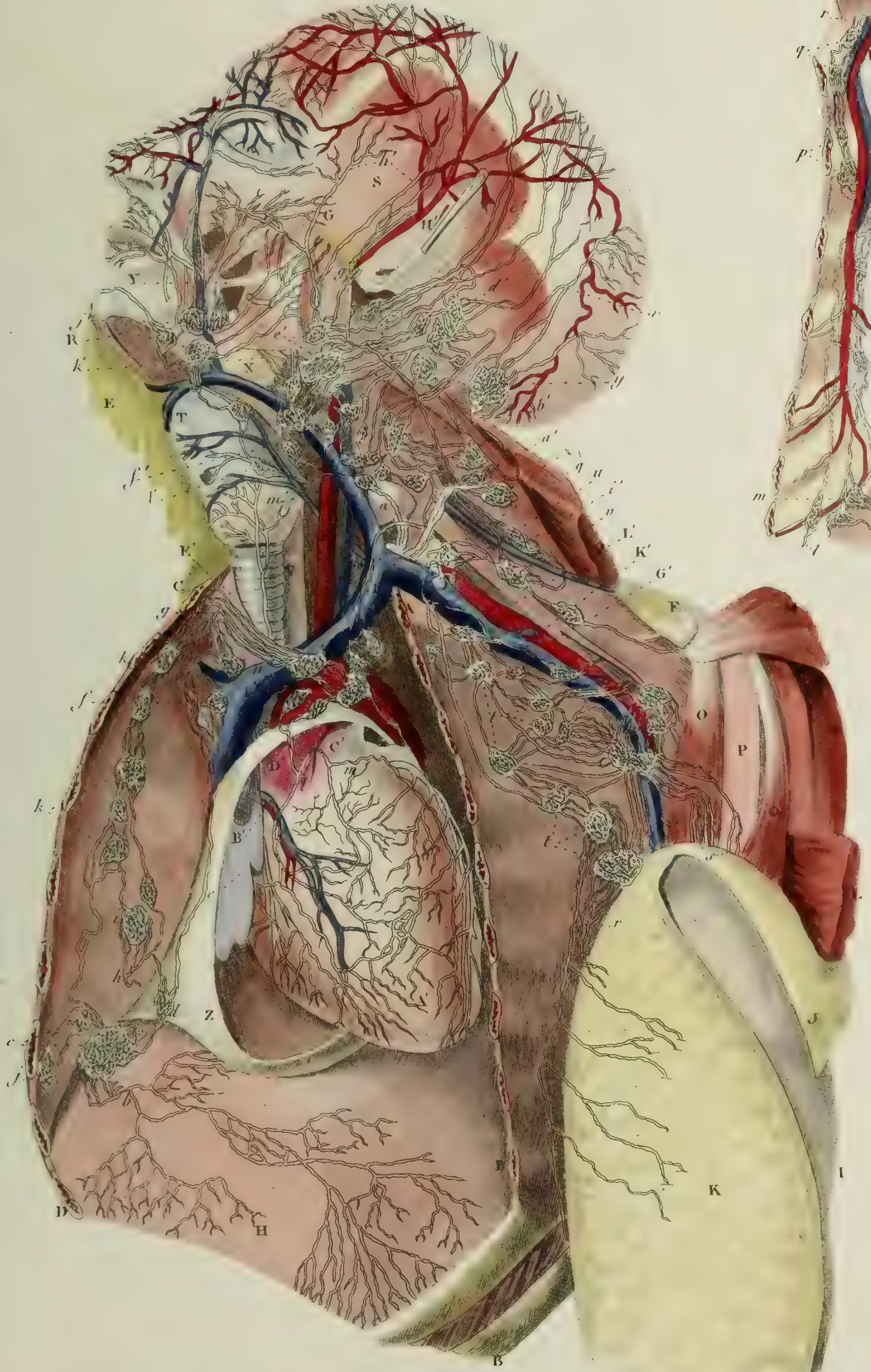

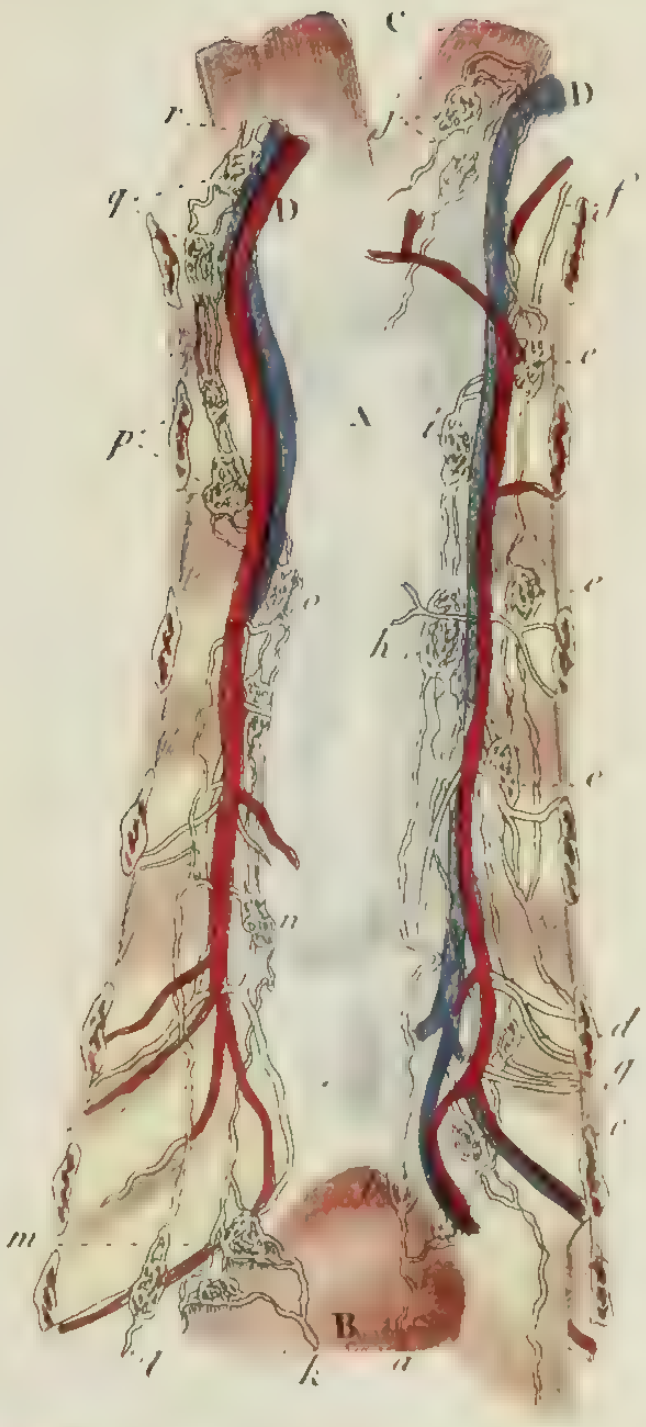

P. Duménil Dir.t

LYMPHATIQUES PROFONDS DE LA POITRINE ET DU COU.

Pr Duménil Dir^t

LYMPHATIQUES PROFONDS DE LA TÊTE ET DU COU.

Fig. 1.

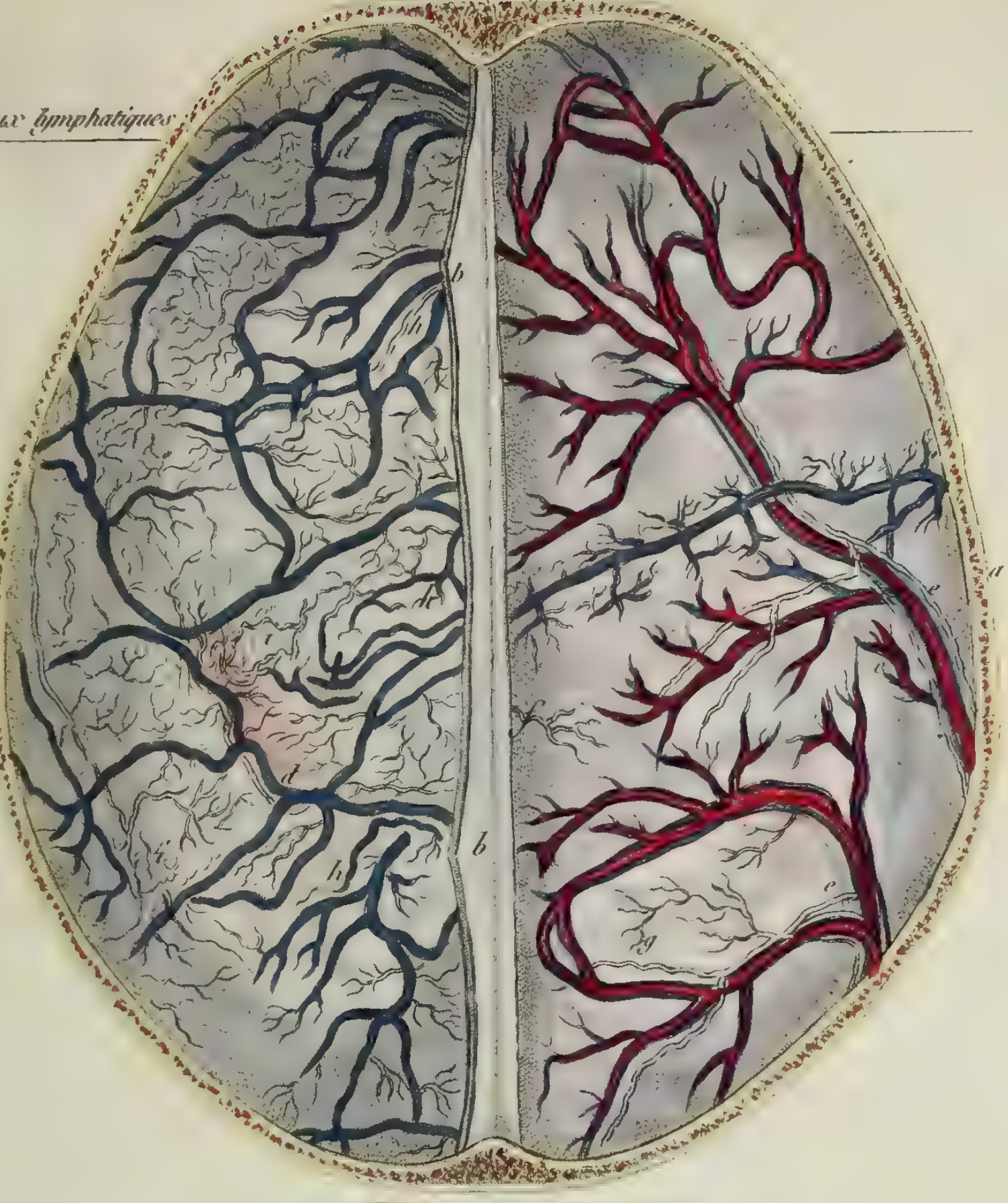

Fig. 2.

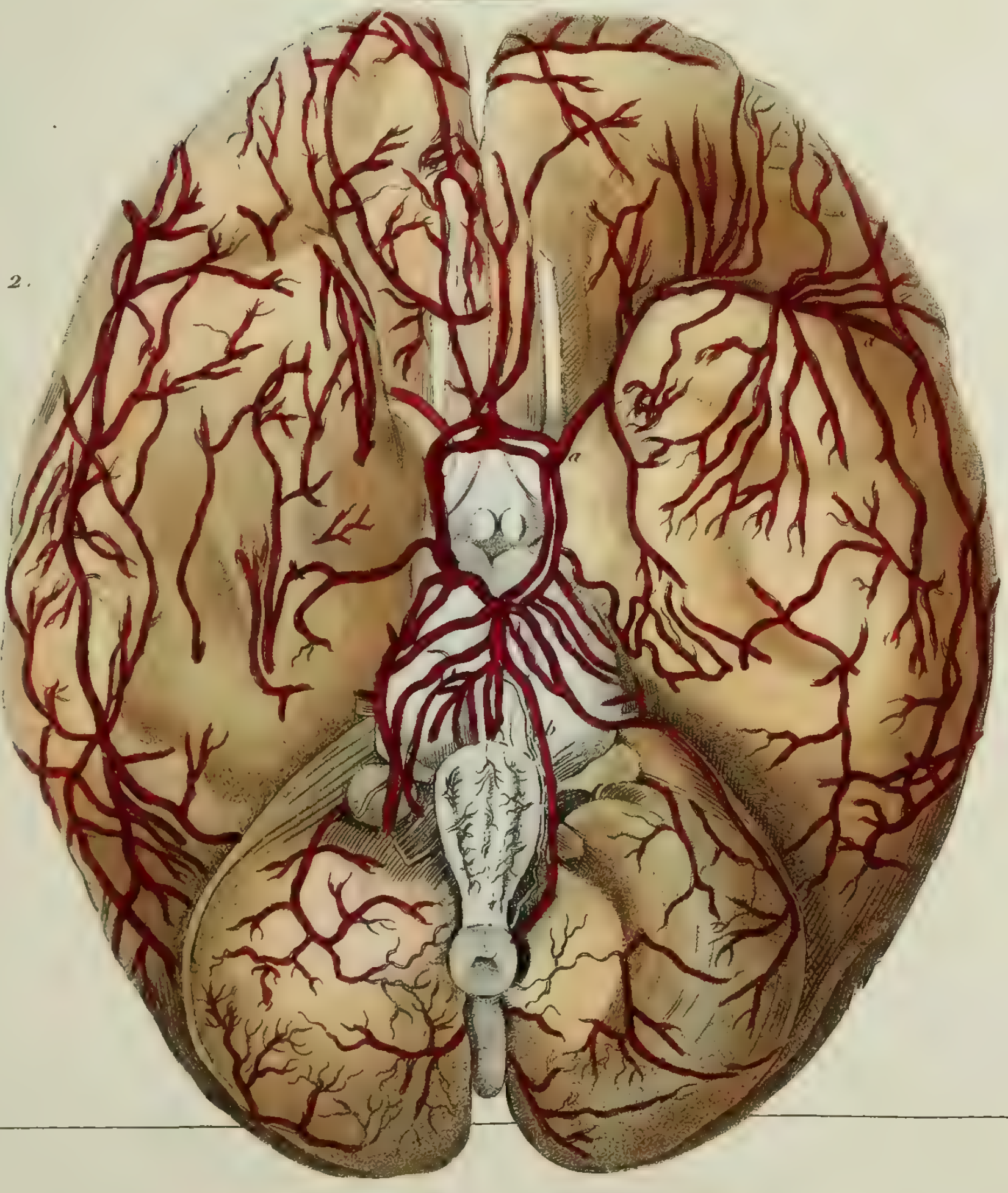

P. Duménil Dir.

LYMPHATIQUES DES MENINGES.